

# 大鼠和小鼠解剖图谱

生物秀—专心做生物！

[www.bb100.com](http://www.bb100.com)

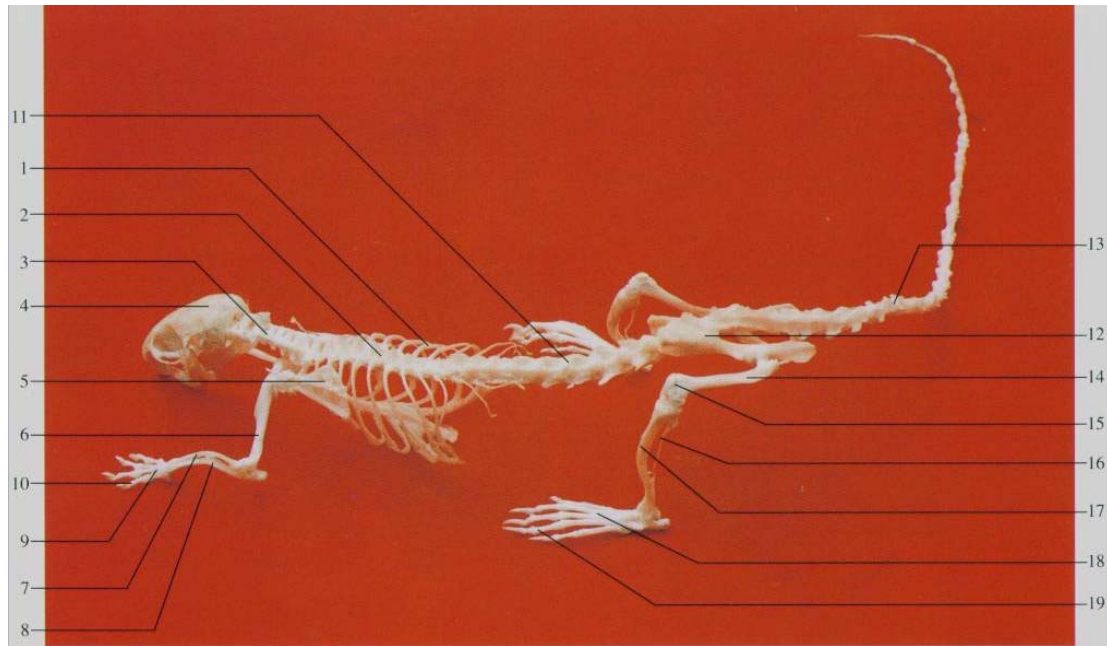
易生物-领先的生物医药商务平台

[www.ebioe.com](http://www.ebioe.com)

生物秀论坛-学术交流,资源共享,互助社区

[www.bb100.com/bbs/](http://www.bb100.com/bbs/)

图VIII-1 整体骨骼侧面观 The skeleton. Lateral View

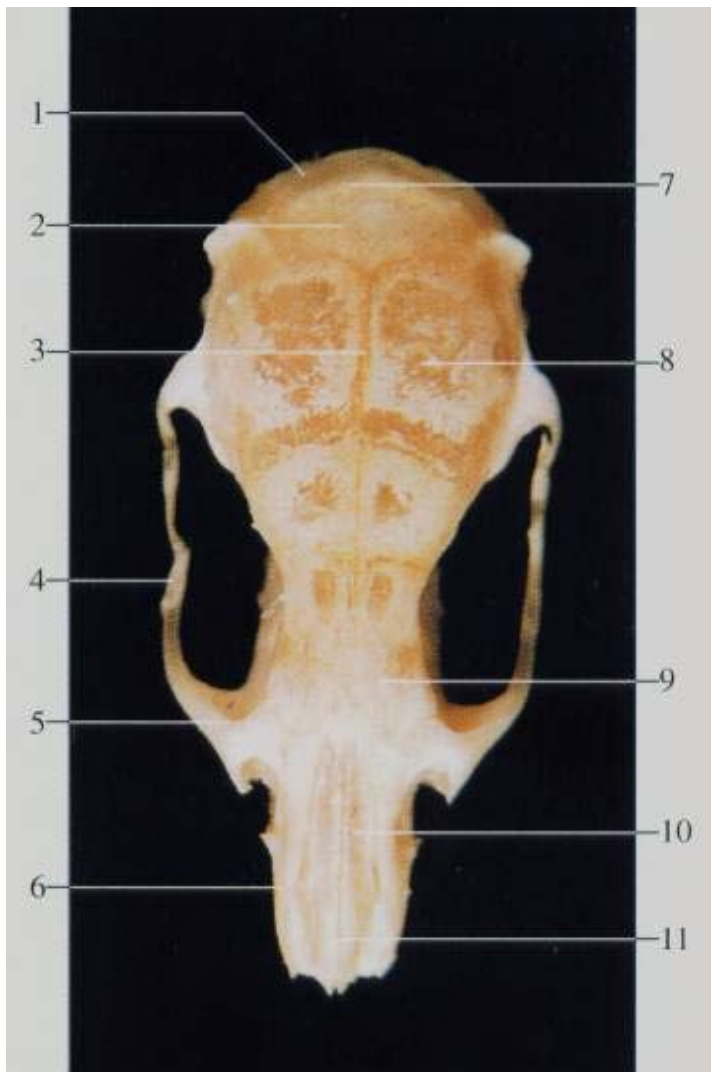

图VIII-2 整体骨骼左前面观 The skeleton. Left anterior view

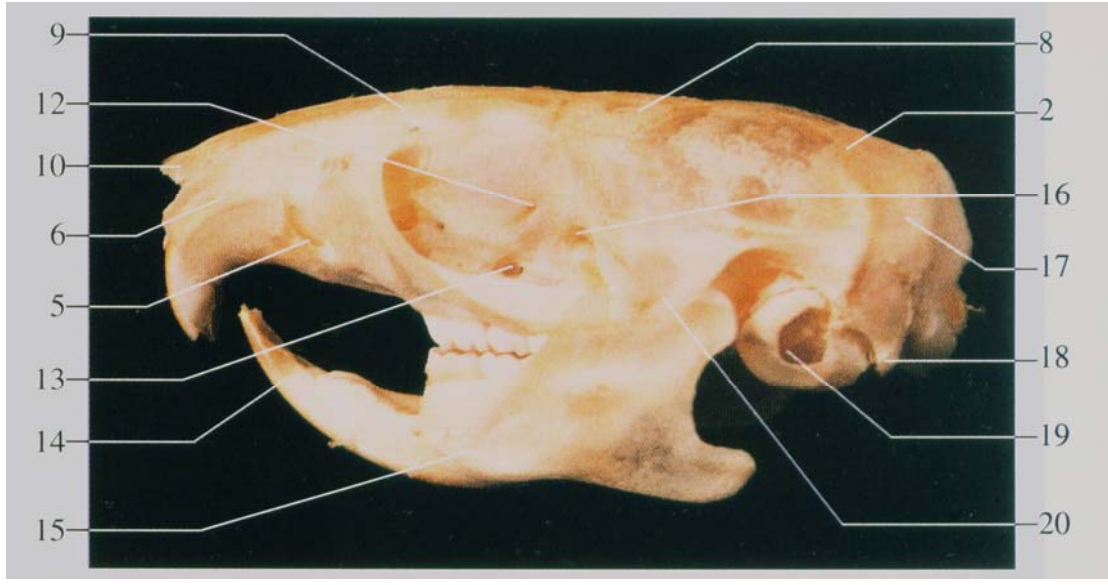
- 1 肋骨 rib
- 2 胸椎 thoracic vertebra
- 3 颈椎 cervical vertebra
- 4 颅骨 cranium
- 5 肩胛骨 scapula
- 6 肱骨 humerus
- 7 桡骨 radius
- 8 尺骨 ulna
- 9 掌骨 metacarpal bone
- 10 指骨 digital bone
- 11 腰椎 lumbar vertebra
- 12 髌骨 ilium
- 13 尾骨 coccyx
- 14 股骨 femur
- 15 髌骨 patella
- 16 腓骨 fibula
- 17 胫骨 tibia
- 18 跖骨 metatarsal bone
- 19 趾骨 digital bone



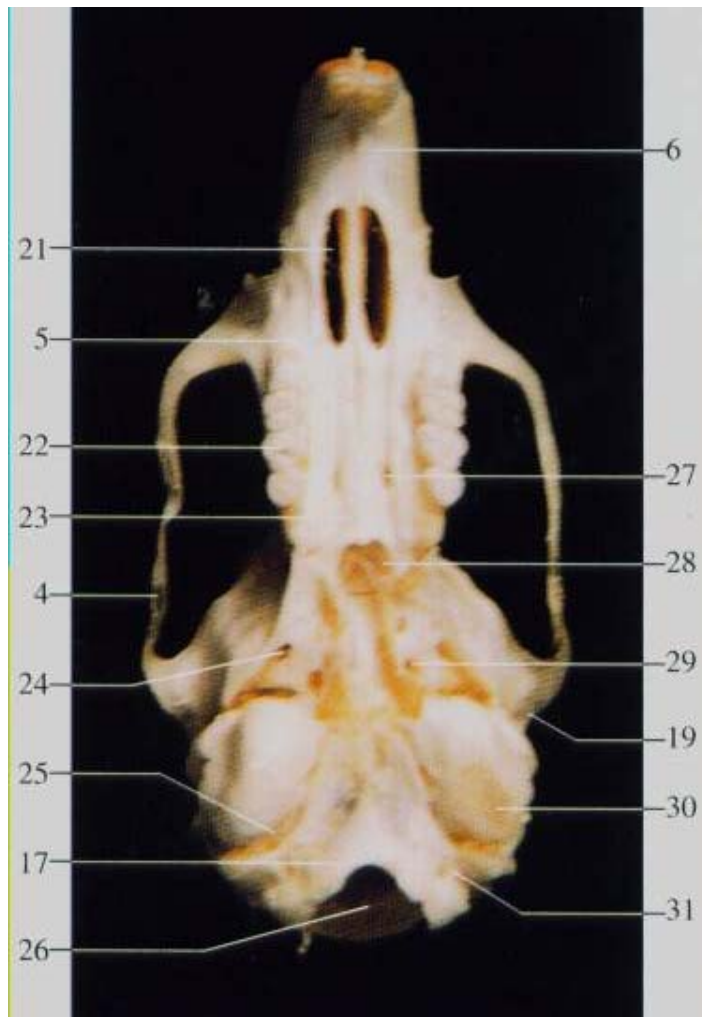图VIII-3 头骨背面 The skull. Dorsal aspect



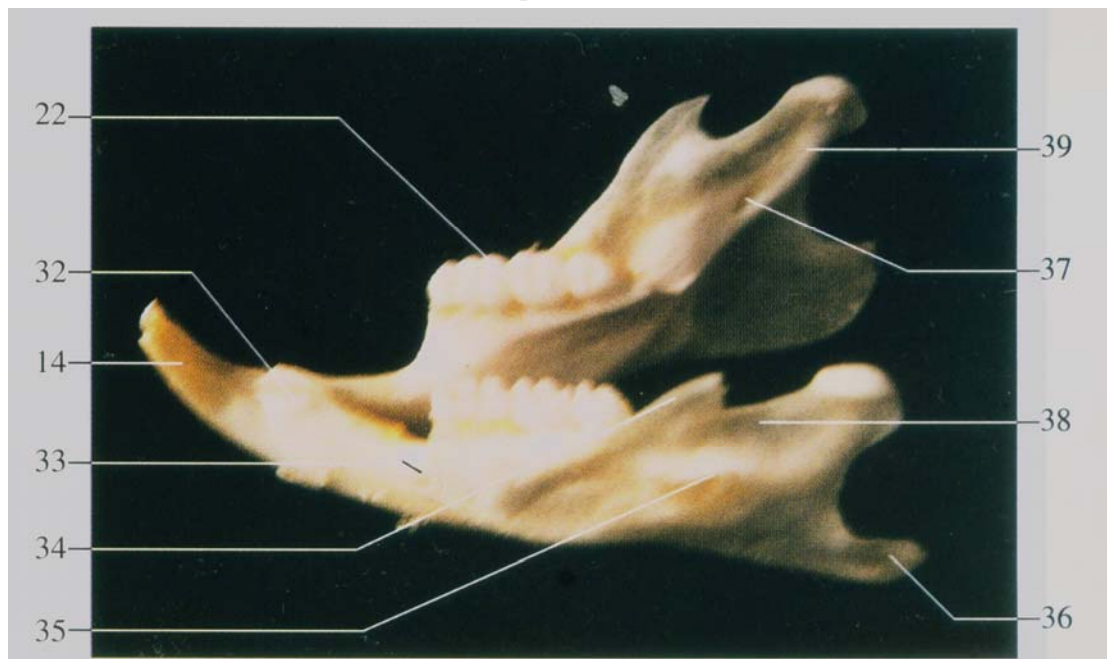
图VIII-4 头骨侧面 The skull. Lateral aspect



图VIII-5 头骨腹面 The skull. Ventral aspect



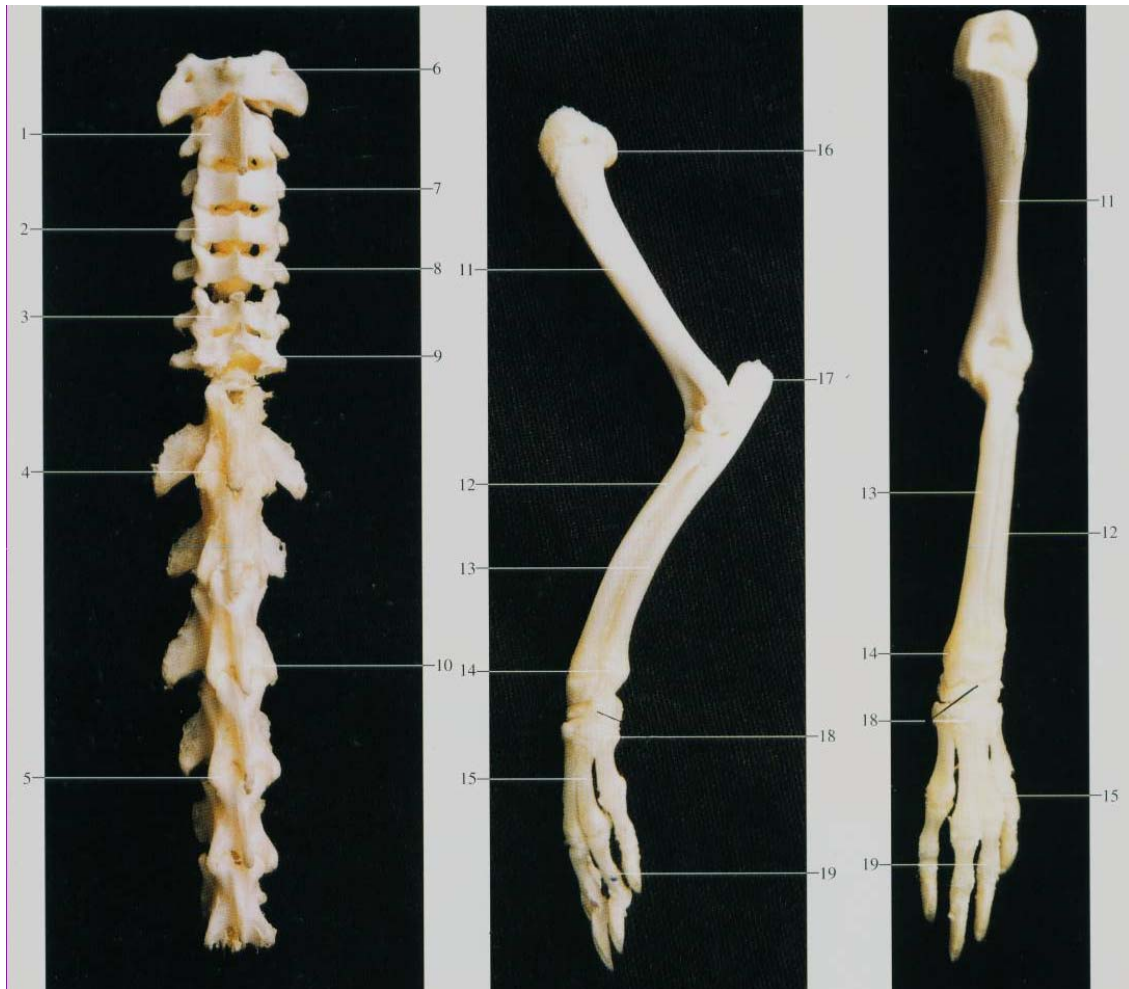
图VIII-6 下颌骨侧面 The mandible. Lateral aspect



- 1 枕骨 occipital bone
- 2 顶间骨 interparietal bone
- 3 矢状缝 sagittal suture
- 4 颧骨 malar bone
- 5 上颌骨 maxillary bone
- 6 前颌骨 premaxillary bone
- 7 枕外嵴 external occipital creat
- 8 顶骨 parietal bone
- 9 额骨 frontal bone
- 10 鼻骨 nasal bone
- 11 鼻间缝 internasal suture
- 12 前筛孔 preethmoid pore
- 13 蝶腭孔 sphenopalatine foramen
- 14 门齿 incisor tooth
- 15 下颌骨 mandible
- 16 视神经孔 optic foramen
- 17 枕骨 occipital bone
- 18 茎突 styloid process
- 19 外耳道 external acoustic meatus
- 20 颞骨 temporal bone
- 21 腭裂 patoschisis
- 22 白齿 molar tooth
- 23 腭骨 palatine bone
- 24 翼孔 pterygoid apertures
- 25 破裂孔 foramen lacerum
- 26 枕大孔 foramen magnum
- 27 腭后孔 posterior palatine foramen
- 28 鼻后孔 posterior nasal apertures
- 29 卵圆孔 foramen ovale
- 30 鼓骨 tympanic bone
- 31 舌下神经孔 hypoglossal foramen
- 32 下颌联合 mandibular symphysis
- 33 颞孔 mental foramen
- 34 冠状突 coronoid process
- 35 下颌支 ramus of mandible
- 36 角状突 process of horn
- 37 下颌孔 mandibular foramen
- 38 翼肌窝 pterygoid fossa
- 39 髁突 condylar process

图VIII-7 颈椎与胸椎背面 The cervical vertebra and thoracic vertebra.Dorsal aspect

图VIII-9 前肢骨背面 The bone of anterior limb.Dorsal aspect



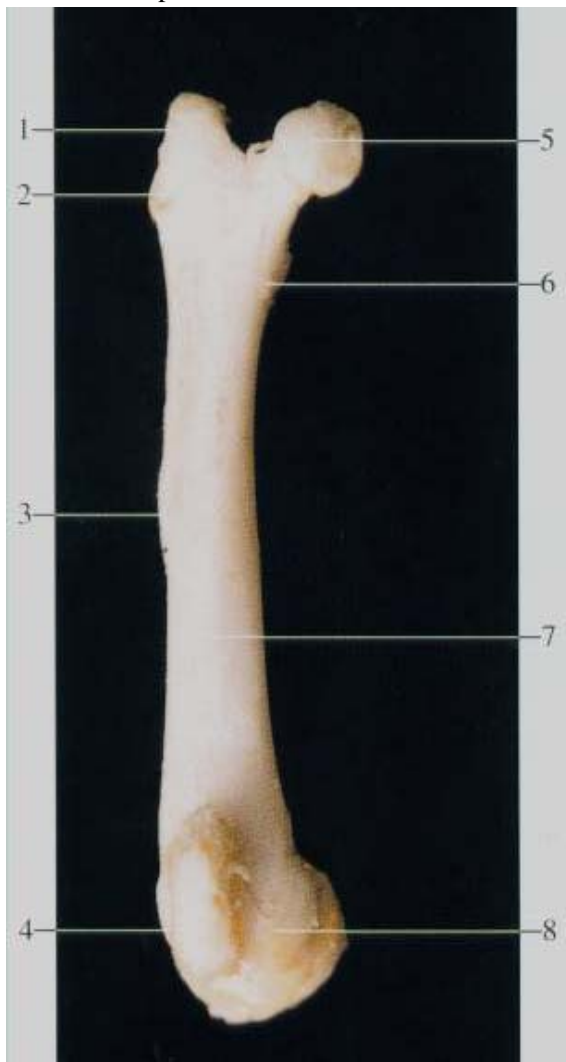
图VIII-8 前肢骨外侧面 The bone of anterior limb. Lateral aspect

- 1 枢椎 axis
- 3 第 6 颈椎 6th cervical vertebra
- 5 第 4 胸椎 4th thoracic vertebra
- 7 第 3 颈椎 3rd cervical vertebra
- 9 第 7 颈椎 7th cervical vertebra
- 11 肱骨体 shaft of humerus
- 13 尺骨 ulna
- 15 掌骨 metacarpal bone
- 17 肘突 cubital process
- 19 指骨 digital bone

- 2 第 4 颈椎 4th cervical vertebra
- 4 第 1 胸椎 1st thoracic vertebra
- 6 寰椎 axis
- 8 第 5 颈椎 5th cervical vertebra
- 10 第 3 胸椎 3rd thoracic vertebra
- 12 桡骨 radius
- 14 尺骨茎突 styloid process of ulna
- 16 肱骨头 head of humerus
- 18 腕骨 carpal bone

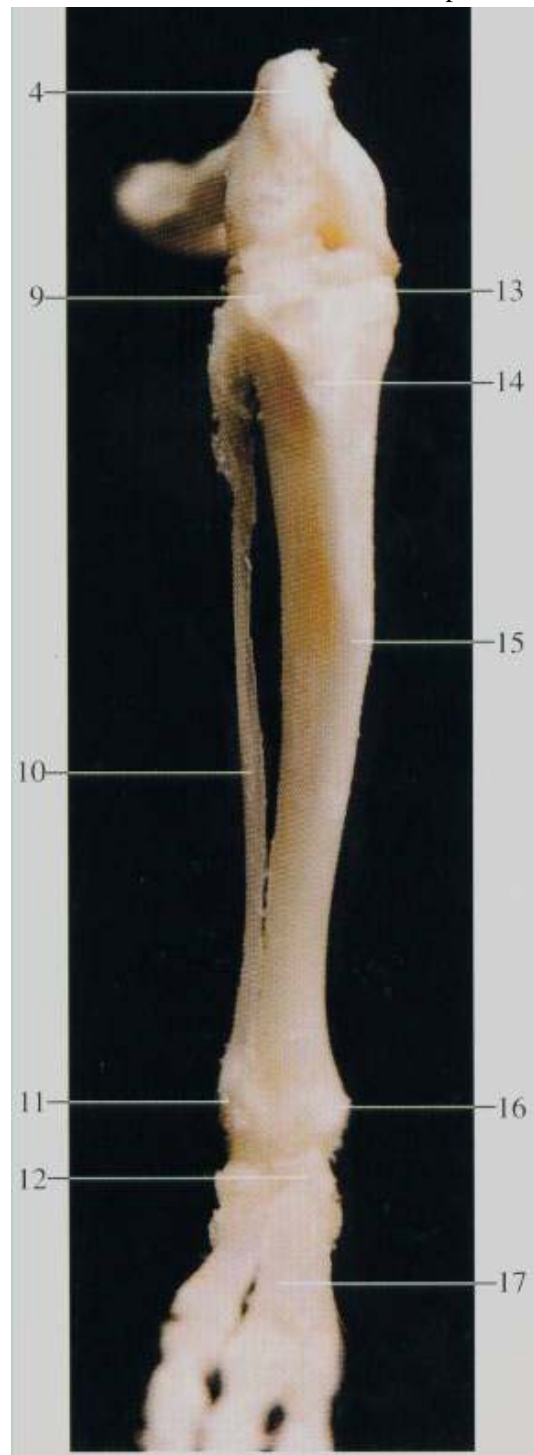
图VIII-10 股骨前面 The femur.

Anterior aspect

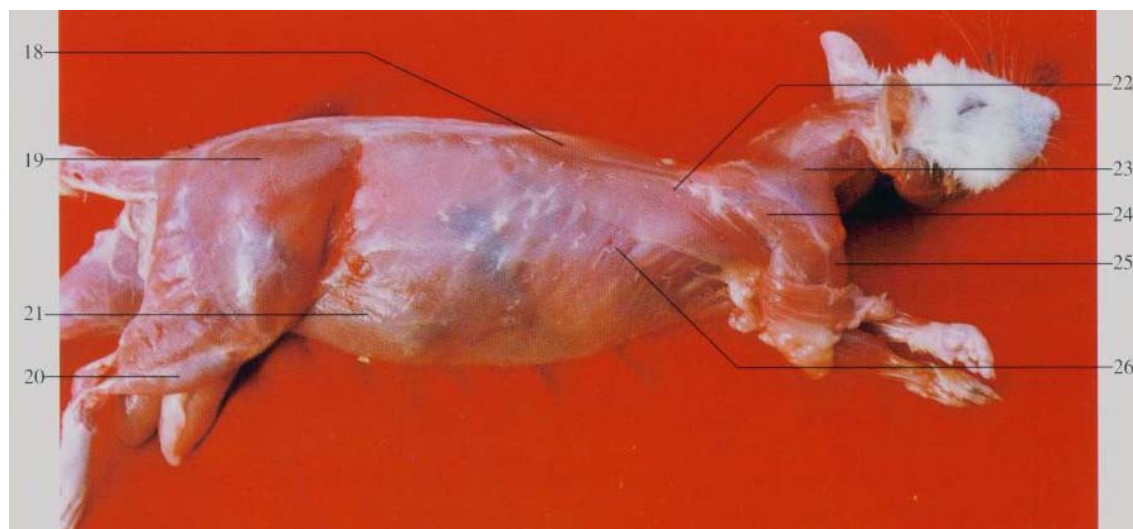

图VIII-11 胫骨与腓骨前面 The tibia and fibula.

Anterior aspect



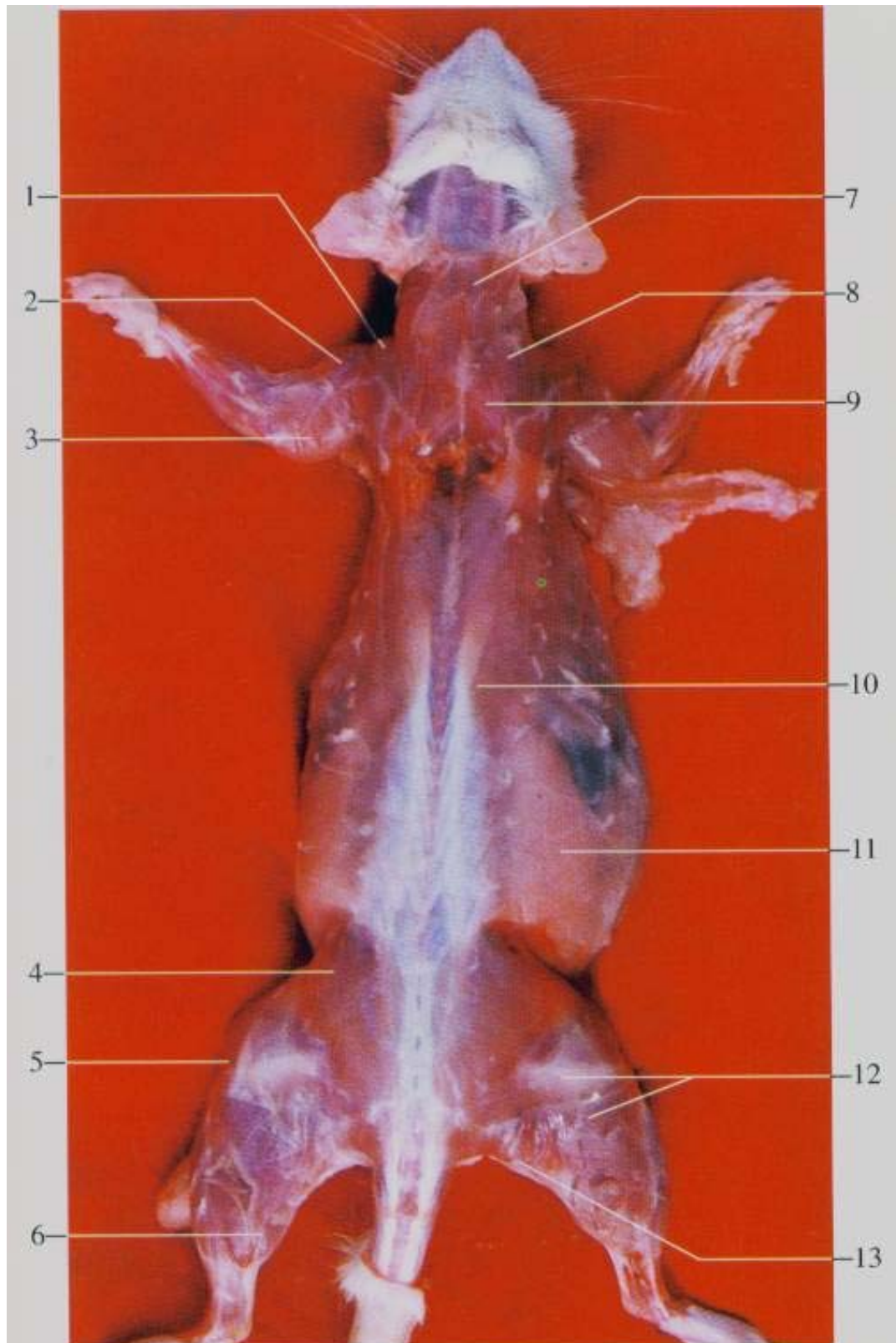
图VIII-12 整体肌侧面观 The muscles. Lateral view



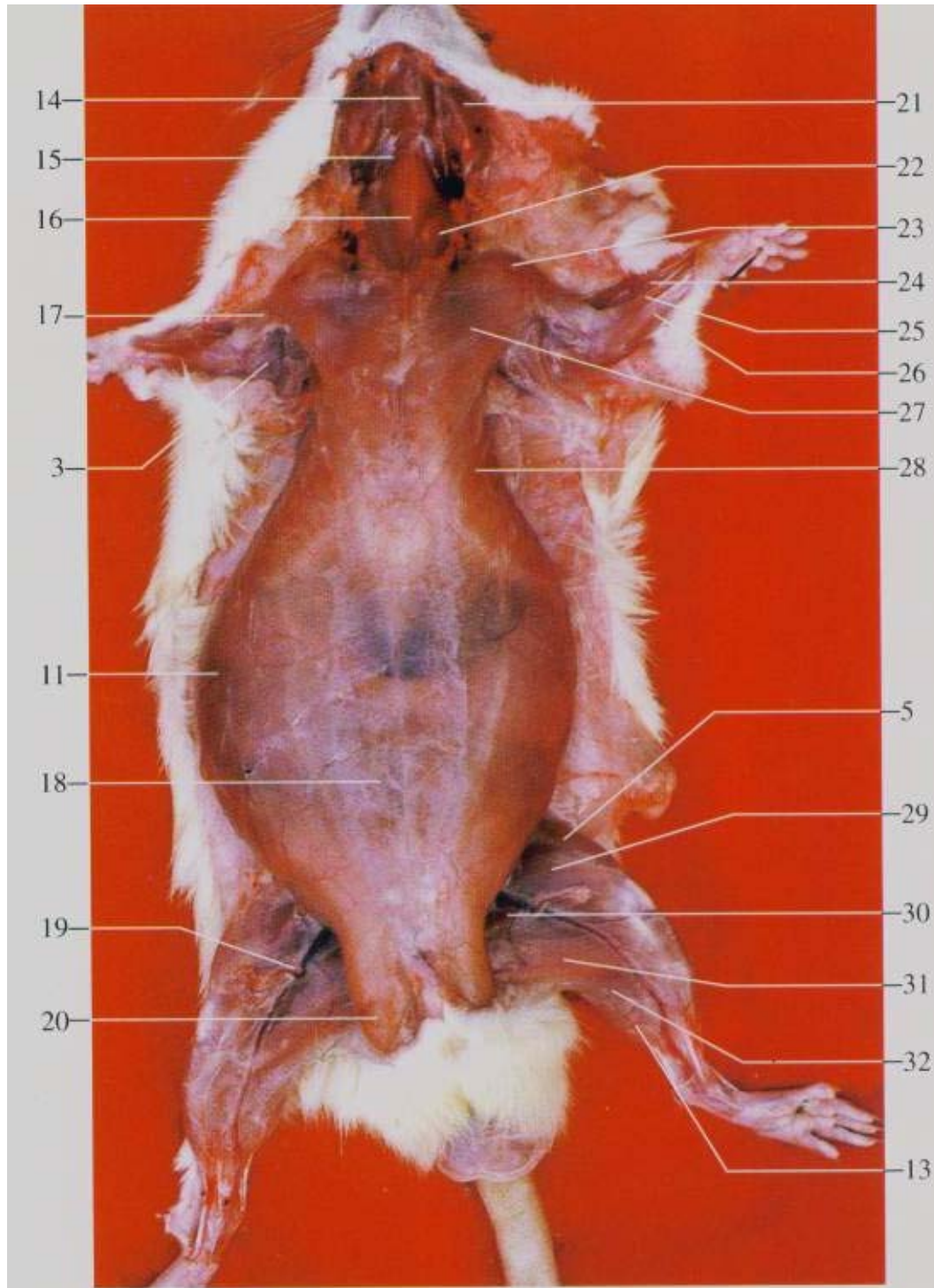
- 1 大转子 greater trochanter
- 2 股骨颈 neck of femur
- 3 第三转子 third trochanter
- 4 髌骨 patella
- 5 股骨头 femoral head
- G 小转子 lesser trochanter
- 7 股骨体 shaft of femur
- 8 股骨内侧髁 medial condyle of femur
- 9 外侧髁 lateral condyle
- 10 腓骨 fibula
- 11 外踝 lateral malleolus
- 12 跗骨 tarsal bone
- 13 胫骨内侧髁 medial condyle of tibia
- 14 胫骨粗隆 tibial tuberosity
- 15 胫骨 tibia
- I6 内踝 medial malleolus
- 17 跖骨 metatarsal bone
- 18 斜方肌 trapezius muscle
- 19 臀浅肌 gluteus superficialis muscle
- 20 股直肌 rectus femoris muscle
- 21 腹外斜肌 external oblique muscle of abdomen
- 22 背阔肌 latissimus dorsi muscle
- 23 肩斜方肌 shoulder-trapezius muscle
- 24 大圆肌 teres major muscle
- 25 肩三角肌 shoulder-deltoid muscle
- 26 前锯肌 serratus anterior muscle



图VIII-13 整体肌背面观 The muscles. Dorsal view



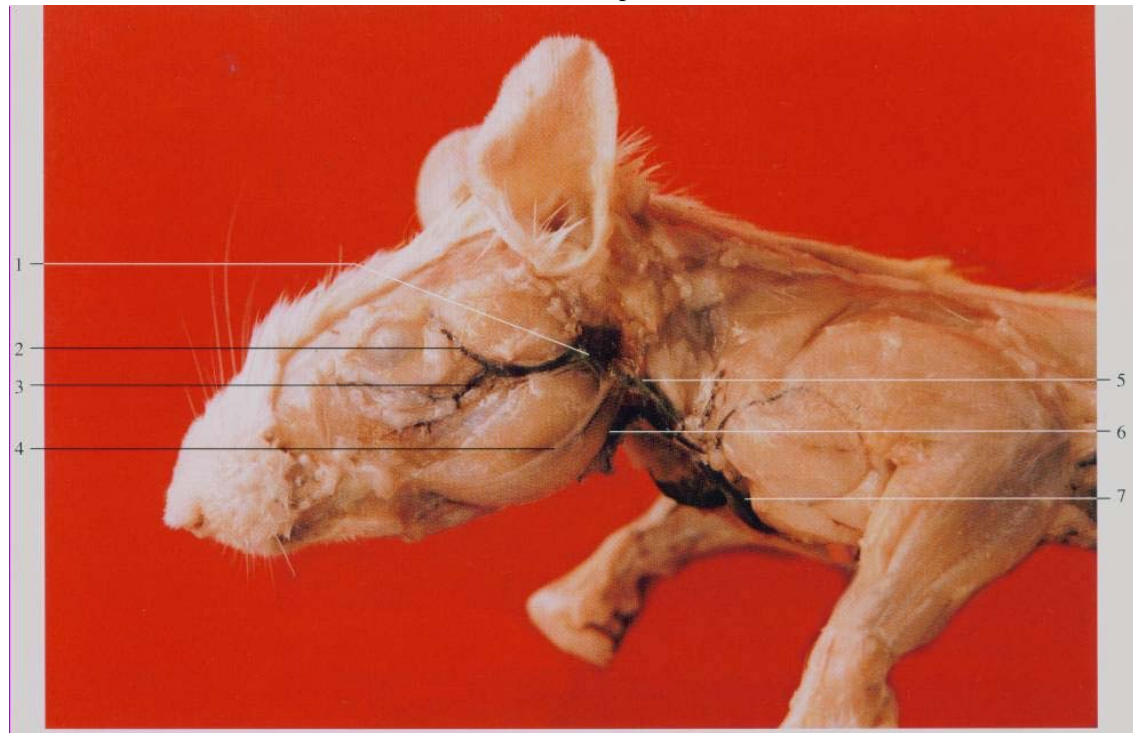
图VIII-14 整体肌腹面观 The muscles. Ventral view



- 1 锁骨提肌 levator clavicle muscle
- 2 肩三角肌 shoulder-deltoid muscle
- 3 肱三头肌 triceps brachii muscle
- 4 臀浅肌 gluteus superficialis muscle
- 5 股直肌 rectus femoris muscle
- 6 腓肠肌 gastrocnemius muscle
- 7 夹肌 splenius muscle

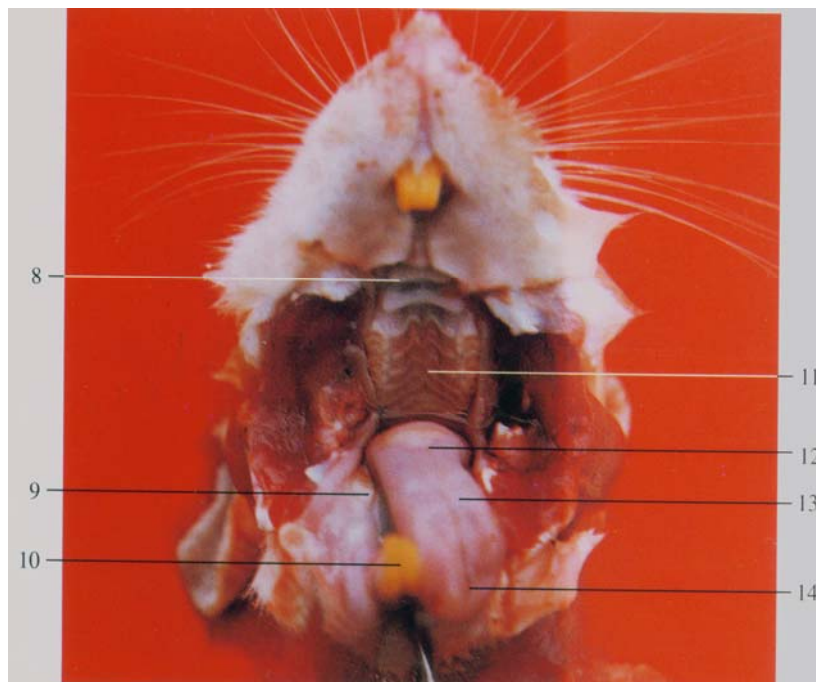
- 8 颈菱形肌 rhomboideus cervicis muscle
- 9 胸菱形肌 rhomboideus pectoralis muscle
- 10 背阔肌 latissimus dorsi muscle
- 11 腹外斜肌 external oblique muscle of abdomen
- 12 股二头肌 biceps femoris muscle
- 13 半腱肌 semitendinosus muscle
- 14 二腹肌前腹 anterior belly of digastric muscle
- 15 二腹肌后腹 posterior belly of digastric muscle
- 16 胸骨舌骨肌 sternohyoid muscle
- 17 肱二头肌 biceps brachii muscle
- 18 腹直肌 rectus abdominis muscle
- 19 股动、静脉 femoral artery and femoral vein
- 20 阴囊 scrotum
- 21 咬肌 masseter muscle
- 22 胸乳突肌 sternomastoideus muscle
- 23 肩三角肌 shoulder-deltoid muscle
- 24 桡侧腕伸肌 extensor carpi radialis muscle
- 25 指总伸肌 extensor digitorum communis muscle
- 26 尺侧腕伸肌 extensor carpi ulnaris muscle
- 27 胸浅肌 pectoral superficialis muscle
- 28 前锯肌 serratus anterior muscle
- 29 股内侧肌 vastus medialis muscle
- 30 耻骨肌 pectineus muscle
- 31 长收肌 adductor longus muscle
- 32 股薄肌 gracilis muscle

图VIII-15 头、颈部侧面 The head and neck. Lateral aspect



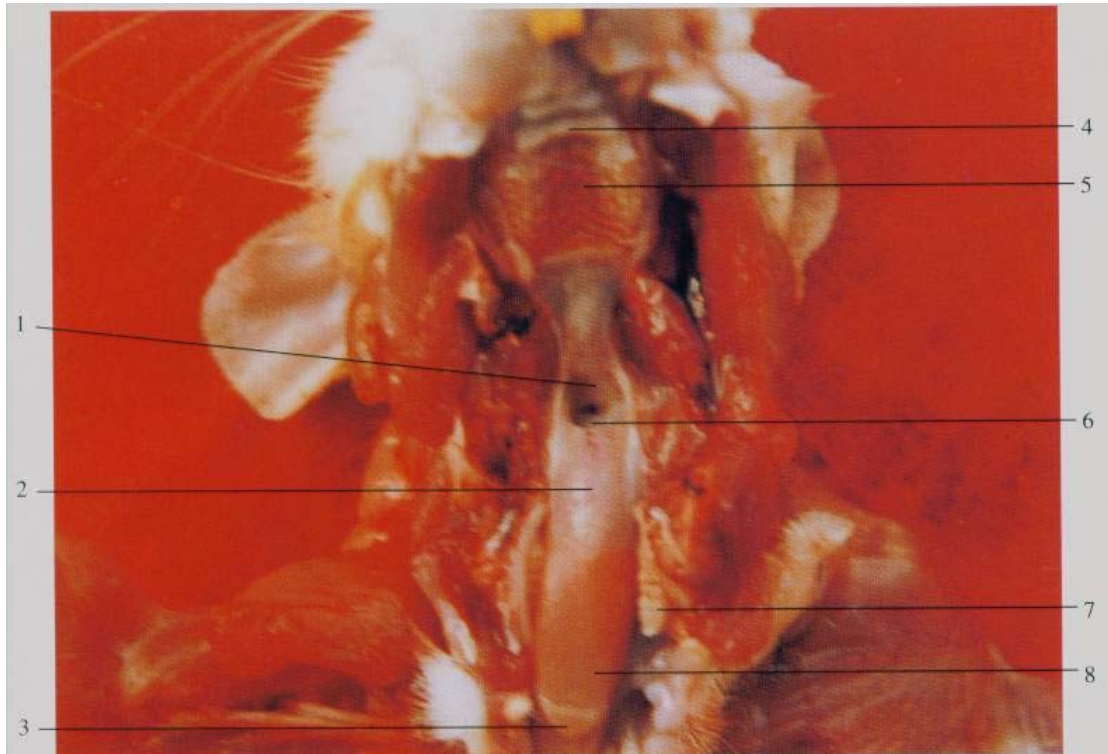- 1 颞浅动、静脉 superficial temporal artery and vein    2 眶上静脉 supraorbital vein  
3 面横动、静脉 transverse facial artery and vein    4 下颌缘神经 marginalmandibular nerve  
5 面后静脉 posterior facial vein  
6 面前静脉 anterior facial vein  
  
7 颈外静脉 external jugular vein

图VIII-16 口腔 (1)The oral cavity (1)

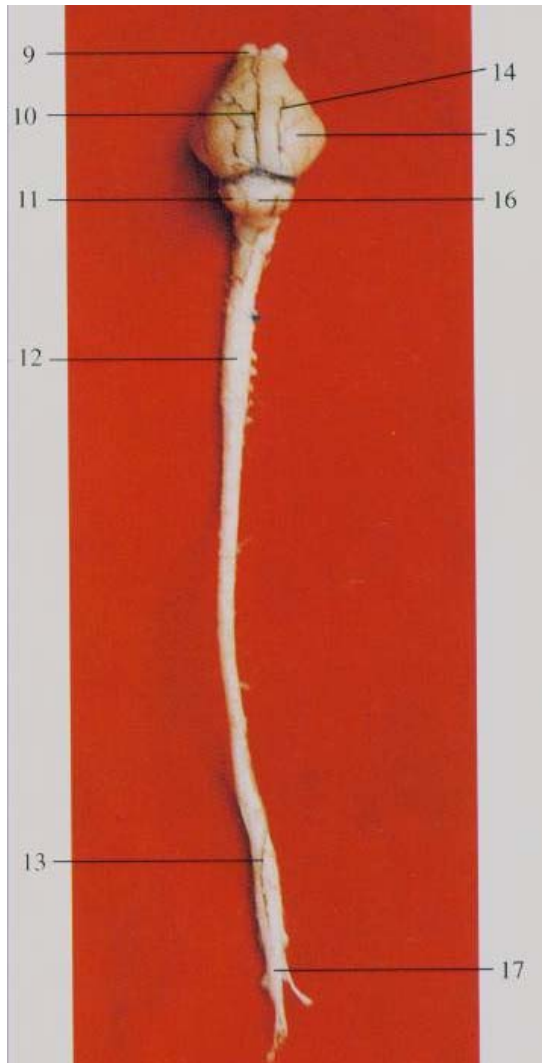


- |   |                                   |
|---|-----------------------------------|
| 1 颞浅动、静脉 superficial temporal artery and vein | 2 眶上静脉 supraorbital vein          |
| 3 面横动、静脉 transverse facial artery and vein    | 4 下颌缘神经 marginal mandibular nerve |
| 5 面后静脉 posterior facial vein                  | 6 面前静脉 anterior facial vein       |
| 7 颈外静脉 external jugular vein                  | 8 硬腭褶 fold of hard palate         |
| 9 臼齿 molar tooth                              | 10 门齿 incisor tooth               |
| 11 软腭 soft palate                             | 12 舌根 root of tongue              |
| 13 舌体 body of tongue                          | 14 舌尖 apex of tongue              |

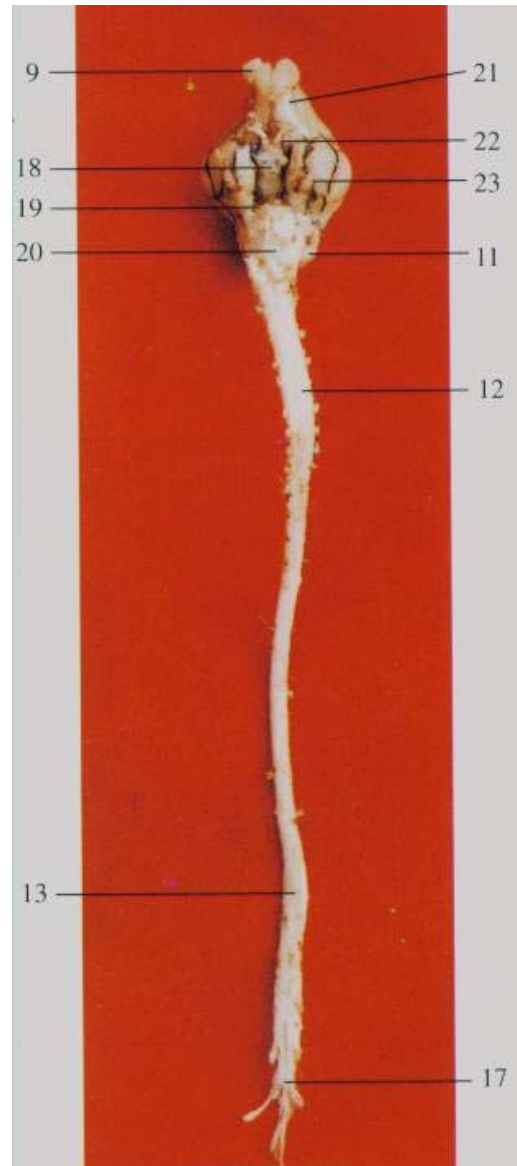
图VIII-17 口腔 (2)The oral cavity (2)



图VIII-18 脑与脊髓背面 The brain and spinal cord.Dorsal aspect



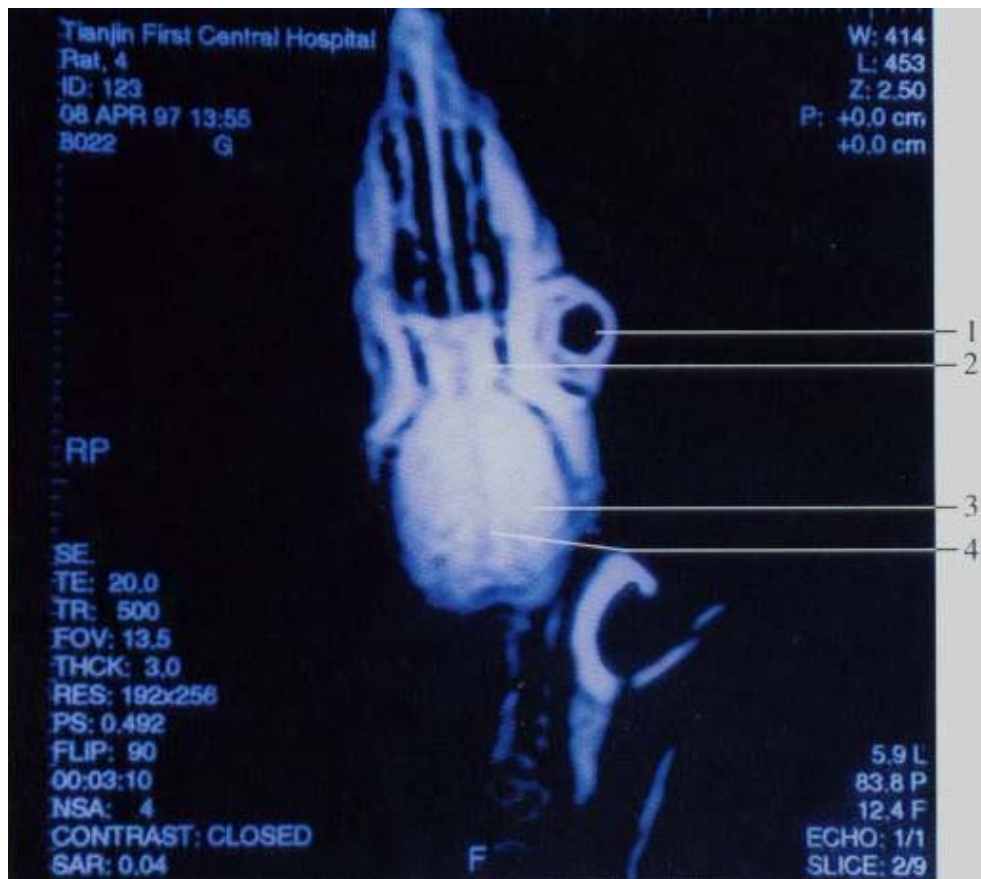图VIII-19 脑与脊髓腹面 The brain and spinal cordVentral aspect



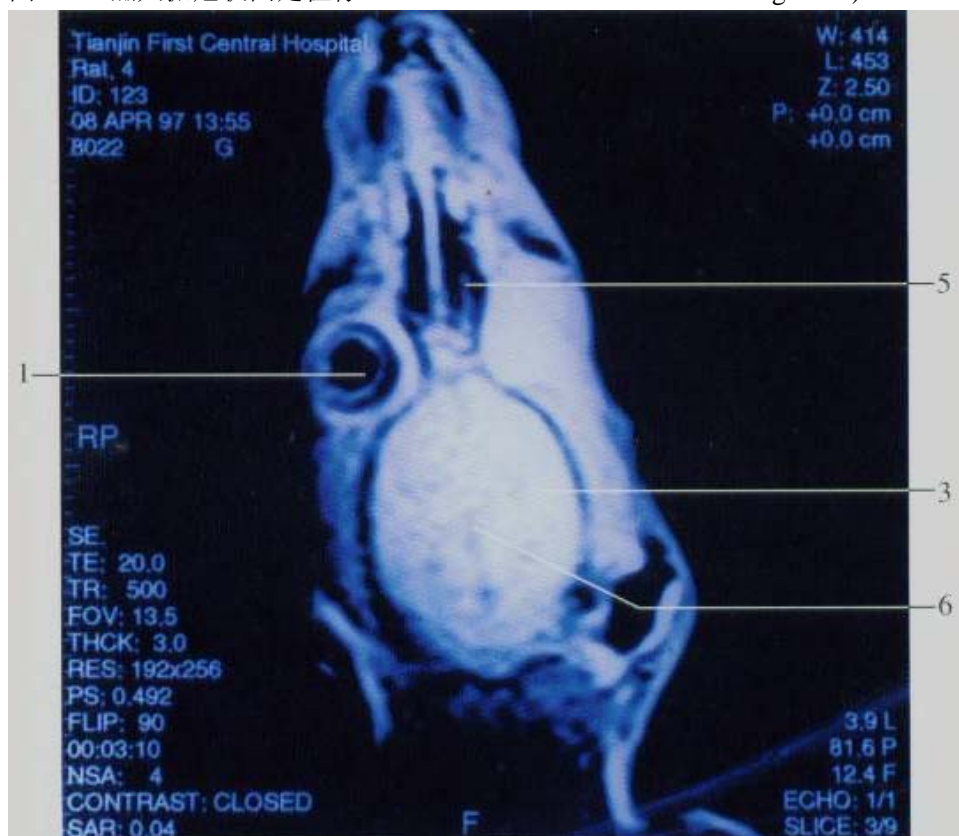
- 1 喉口 aperture of larynx
- 2 舌根 root of tongue
- 3 舌尖 apex of tongue
- 5 软腭 soft palate
- 7 白齿 molar tooth
- 9 嗅球 olfactory bulb
- 11 绒球 flocculus
- 13 腰膨大 lumbar enlargement
- 15 大脑 cerebrum
- 17 脊髓圆锥 courts medullaris
- 19 脑桥 pons
- 21 嗅束 olfactory tract
- 23 三叉神经 trigeminal nerve

- 4 硬腭褶 fold of hard palate
- 6 会厌 epiglottis
- 8 舌体 body of tongue
- 10 中央纵裂 central longitudinal fissure
- 12 颈膨大 cervical enlargement
- 14 外侧纵沟 lateral longitudinal sulcus
- 16 小脑（中央部）cerebellum (central part)
- 18 脑垂体 pituitary gland
- 20 延髓 myelencephalon
- 22 视神经 optic nerve

图VIII-20 磁共振冠状面定位像 (1) The scout view of coronal images (1)



图VIII-21 磁共振冠状面定位像 (2) The scout view of coronal images (2)





1 眼球 eyeball

2 嗅脑 rhinencephalon

3 大脑皮层 cerebral cortex

4 大脑镰 cerebral faix

5 鼻旁窦 paranasal sinus

6 纵裂 longitudinal fissure

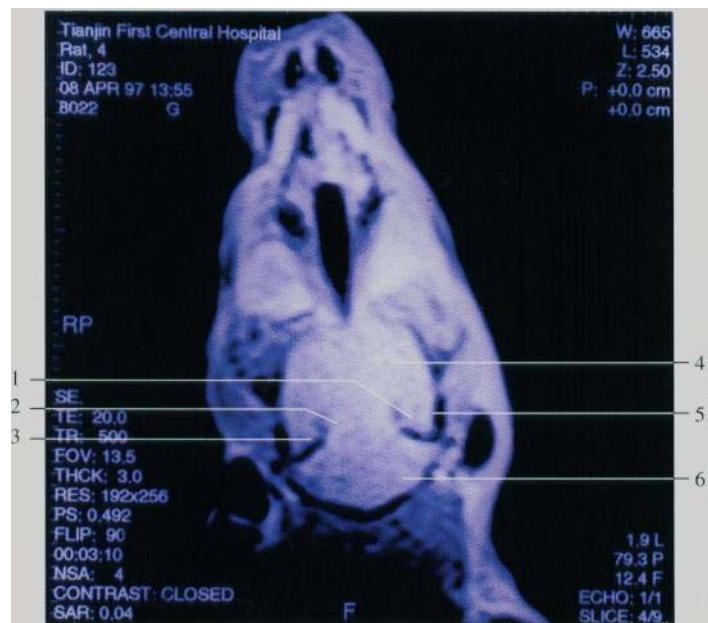
冠状面T<sub>1</sub>加权像，颞颌关节线圈，

SE 序列，层厚 3.0mm，无间隔，

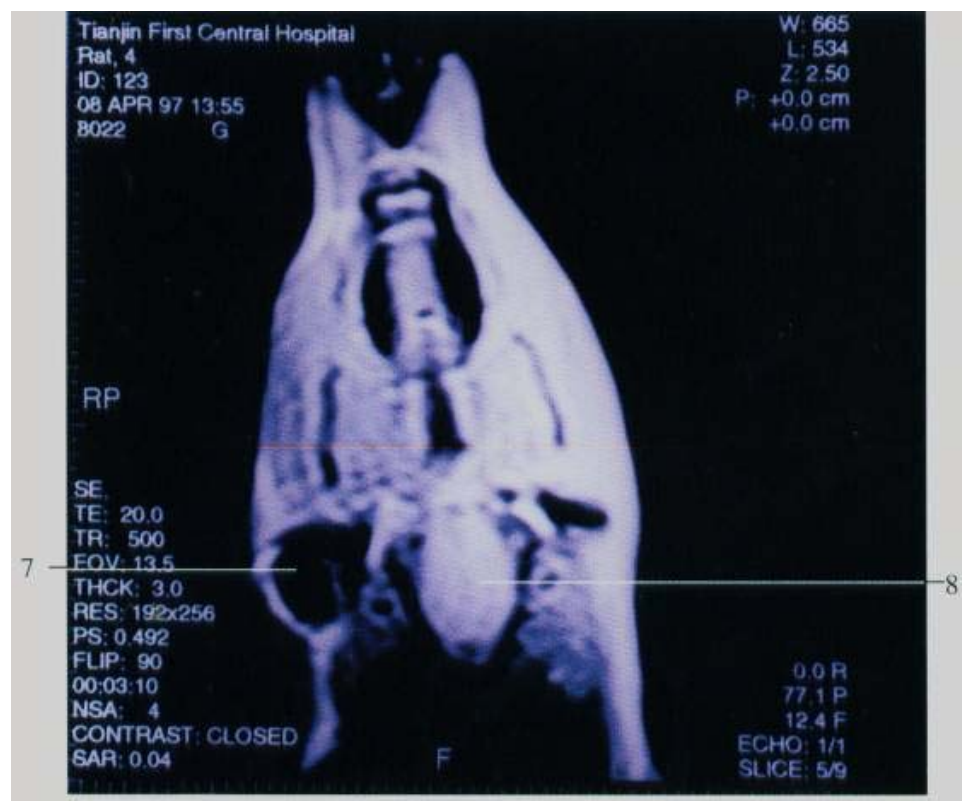TR=500ms，TE=20ms。

扫描方向：从背侧向腹侧。

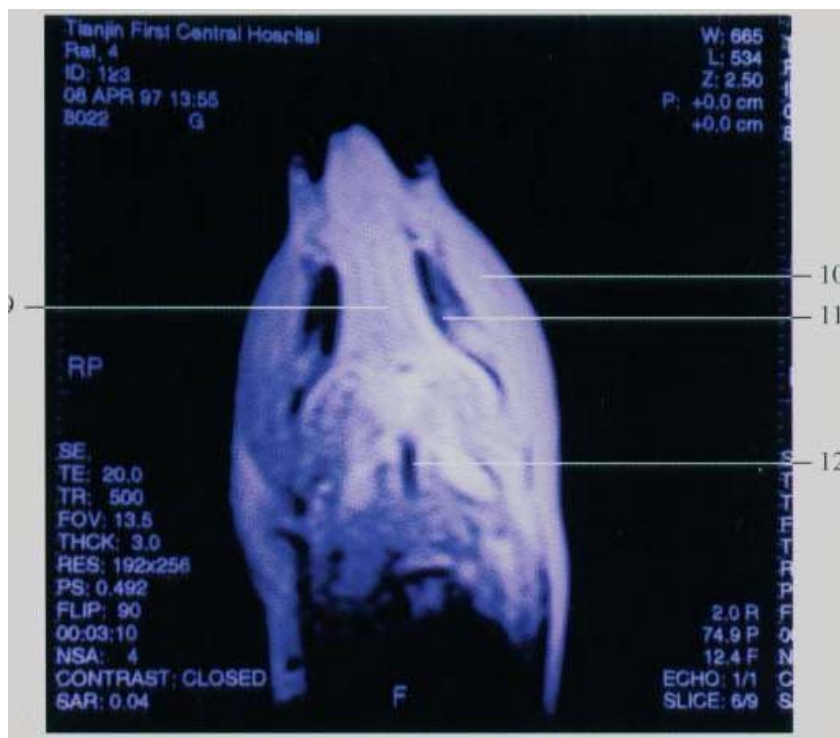图VIII-22 磁共振冠状面定位像 (3) The scout view of coronal images (3)



图VIII-23 磁共振冠状面定位像 (4) The scout view of coronal images (4)

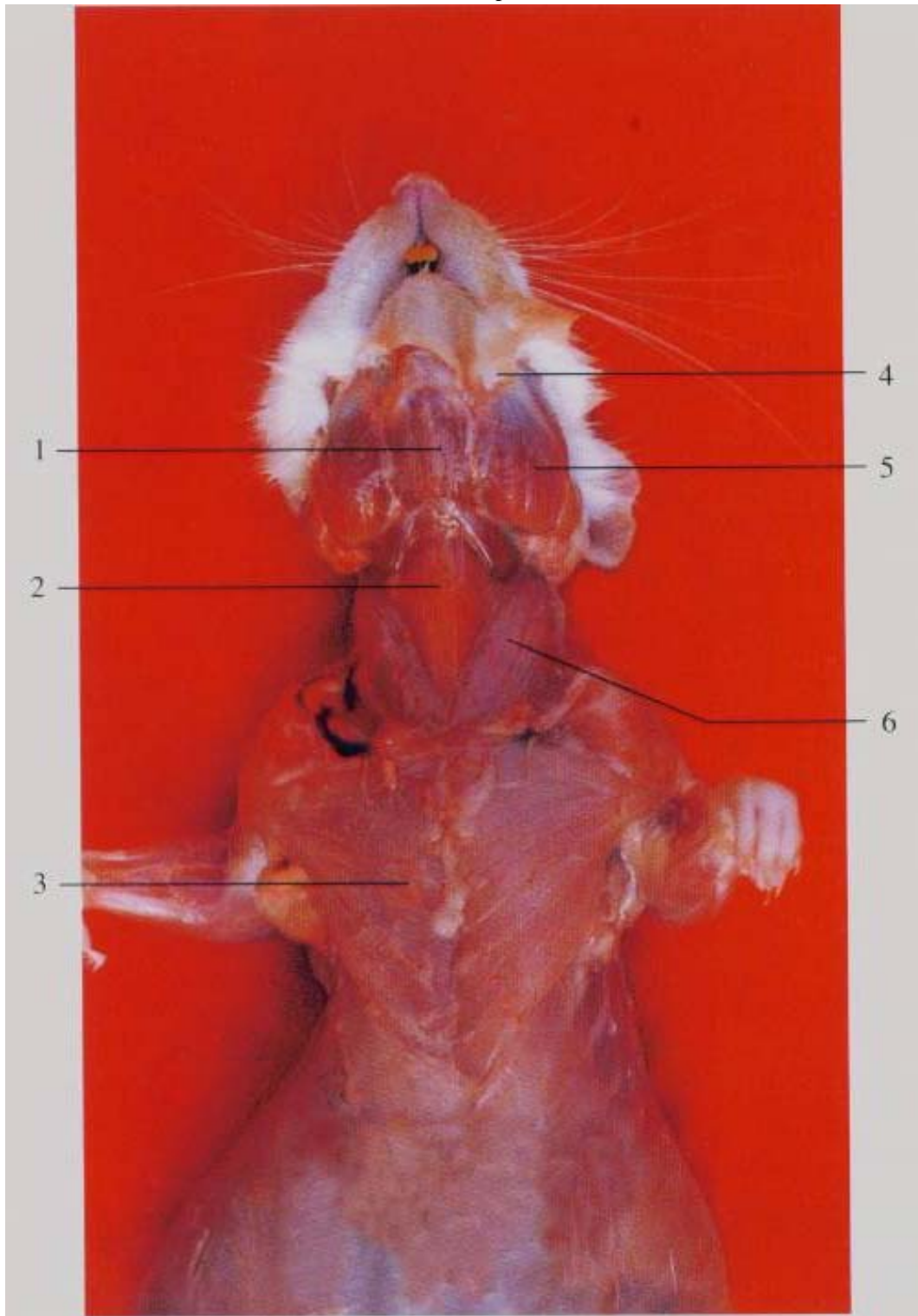


图VIII-24 磁共振冠状面定位像 (5)The scout view of coronal images (5)

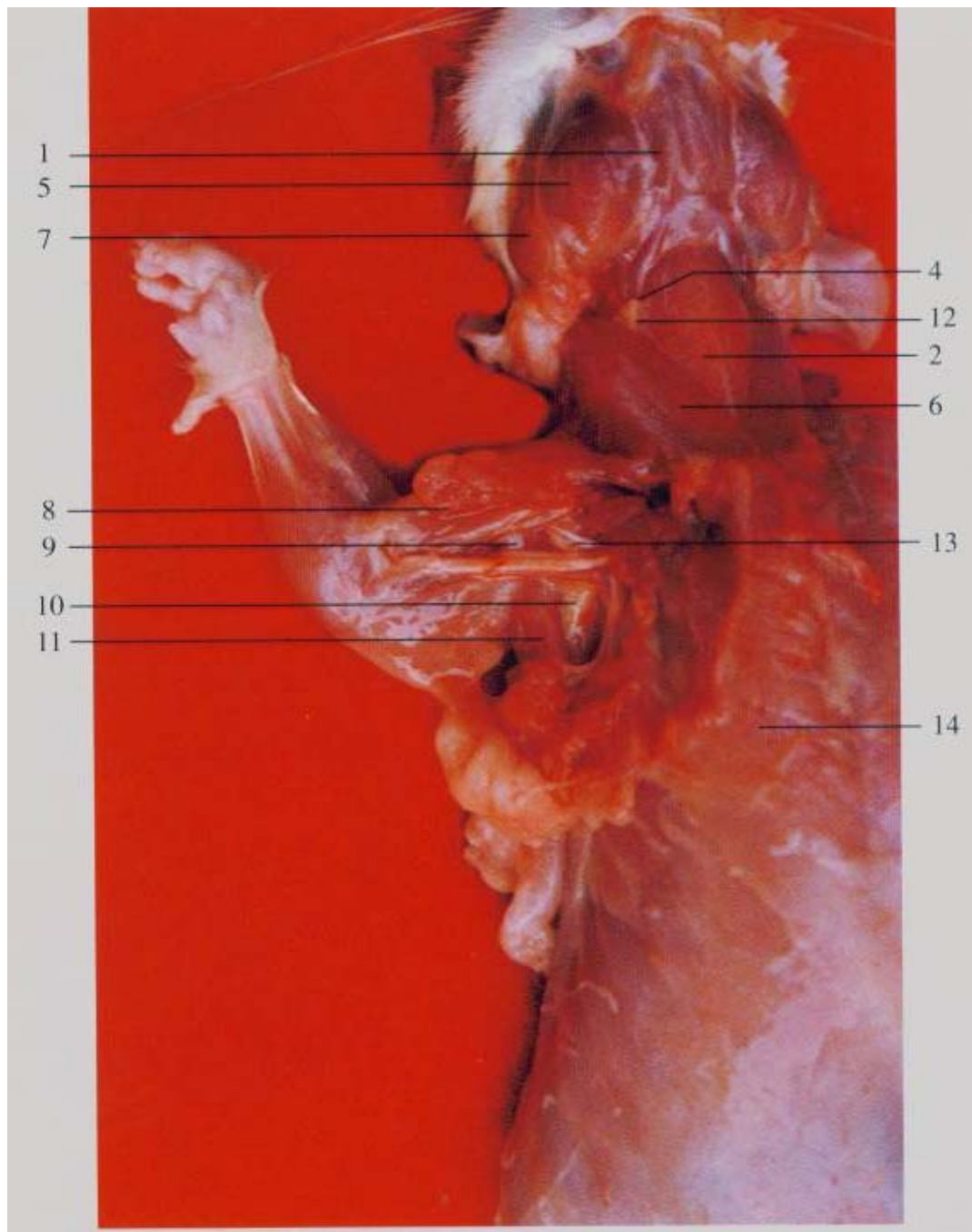


- 1 海马结构 hippocampal formation
- 2 中脑 midbrain
- 3 天幕 tentorium
- 4 额顶叶皮层 frontoparietal cortex
- 5 颞叶皮层 temporal cortex
- G 小脑 cerebellum
- 7 颞骨 temporal bone
- 8 脑桥 pons
- 9 舌 tongue
- 10 咬肌 masseter muscle
- 11 下颌骨 mandible
- 12 咽 pharynx

图VIII-25 颈肌与胸肌 (1)The muscle of neck and pectoral muscle (1)

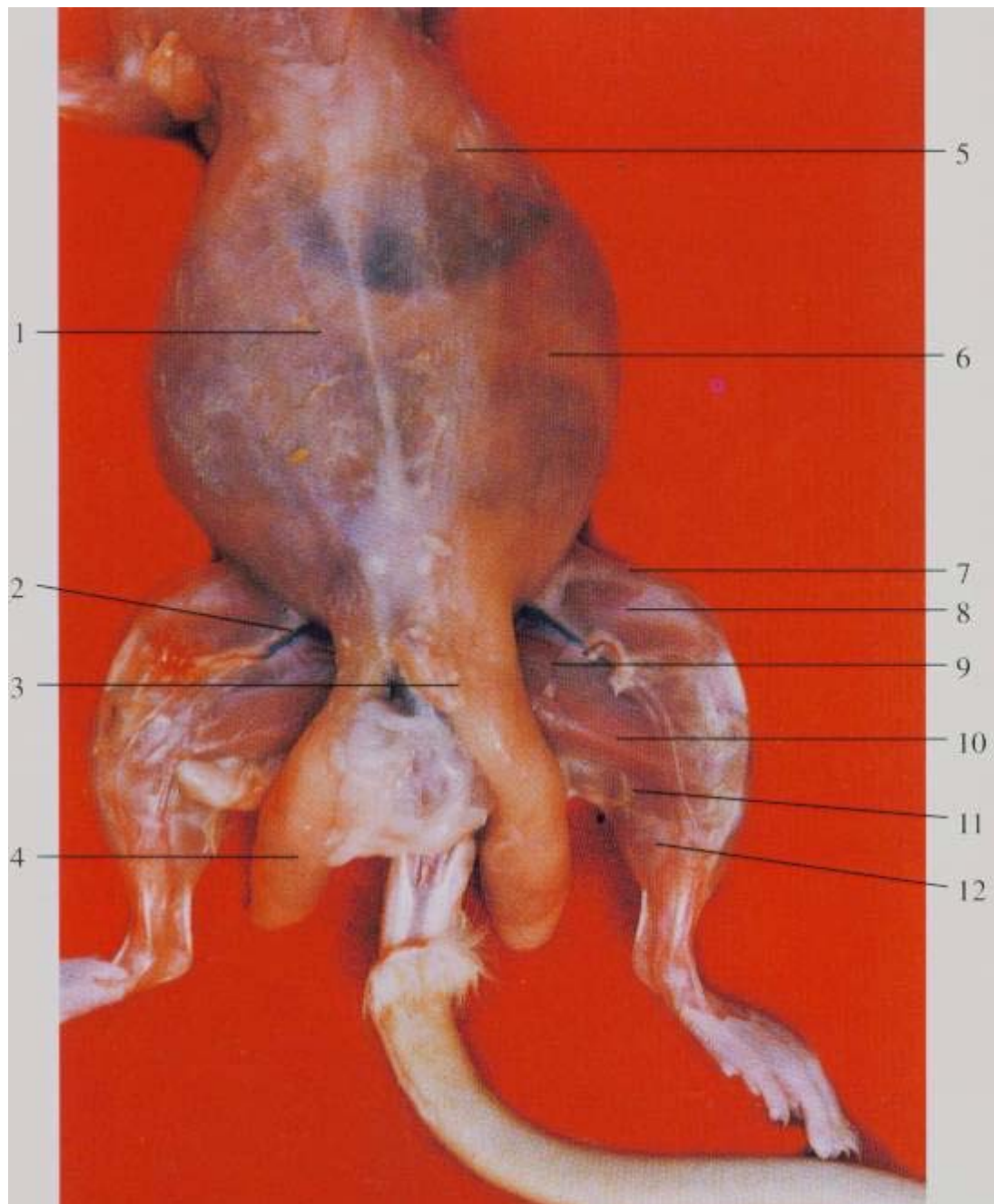

图VIII-26 颈肌与胸肌 (2) The muscle of neck and pectoral muscle (2)

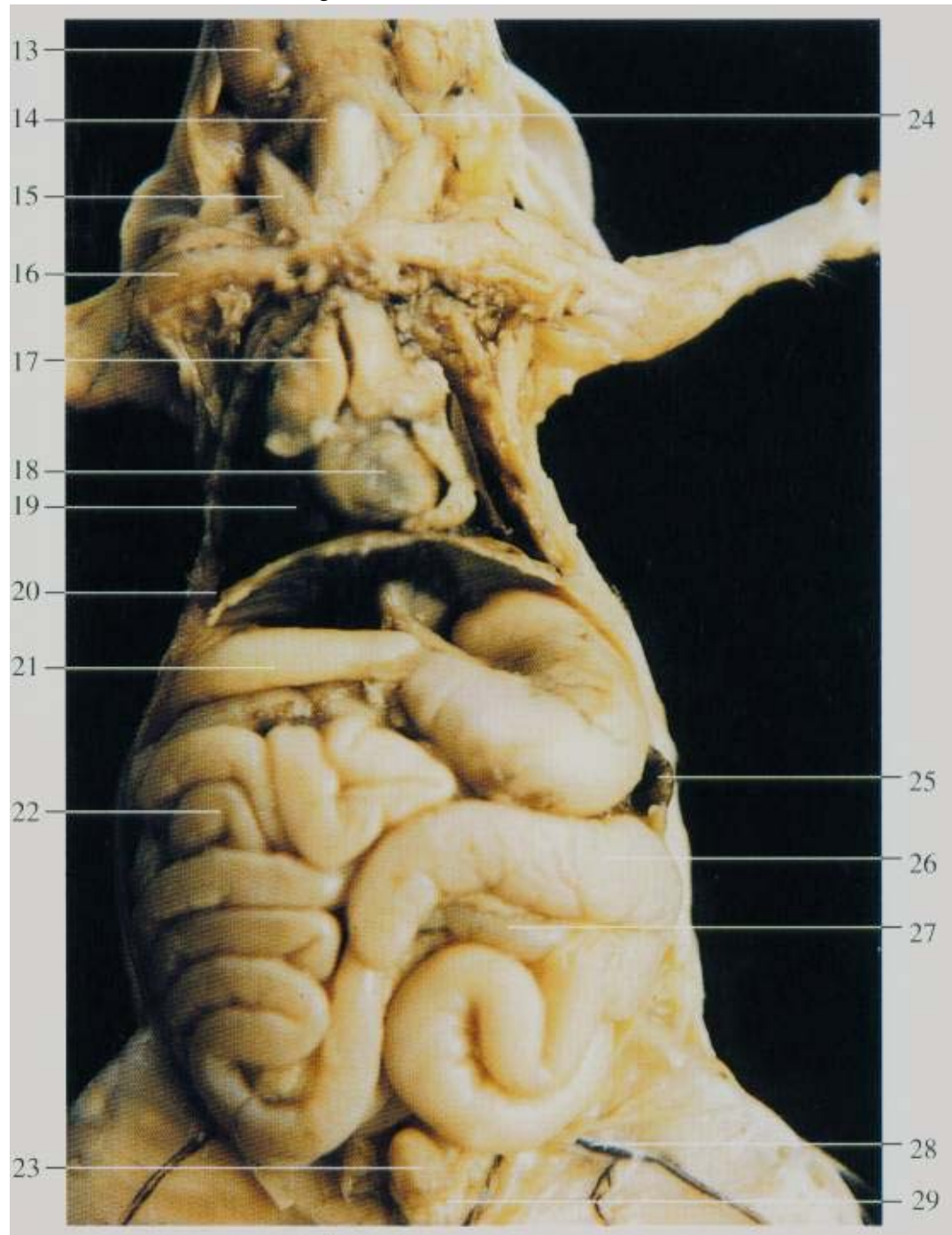


- |  |   |
|--|---|
| 1 二腹肌前腹 anterior belly of digastric muscle | 2 胸骨舌骨肌 sternohyoid muscle                  |
| 3 胸浅肌 pectoral superficialis muscle        | 4 二腹肌后腹 posterior belly of digastric muscle |
| 5 咬肌 masseter muscle                       | 6 胸乳突肌 sternomastoideus muscle              |
| 7 淋巴结 lymph nodes                          | 8 肱二头肌 biceps brachii muscle                |
| 9 桡神经 radial nerve                         | 10 正中神经 median nerve                        |
| 11 背阔肌 latissimus dorsi muscle             | 12 肩胛舌骨肌 omohyoid muscle                    |
| 13 腋神经 axillary nerve                      | 14 胸深肌 pectoral profundus muscle            |

图VIII-27 腹肌 The abdominal muscle



图VIII-28 胸、腹腔器官 The organs in the thoracic and abdominal cavities

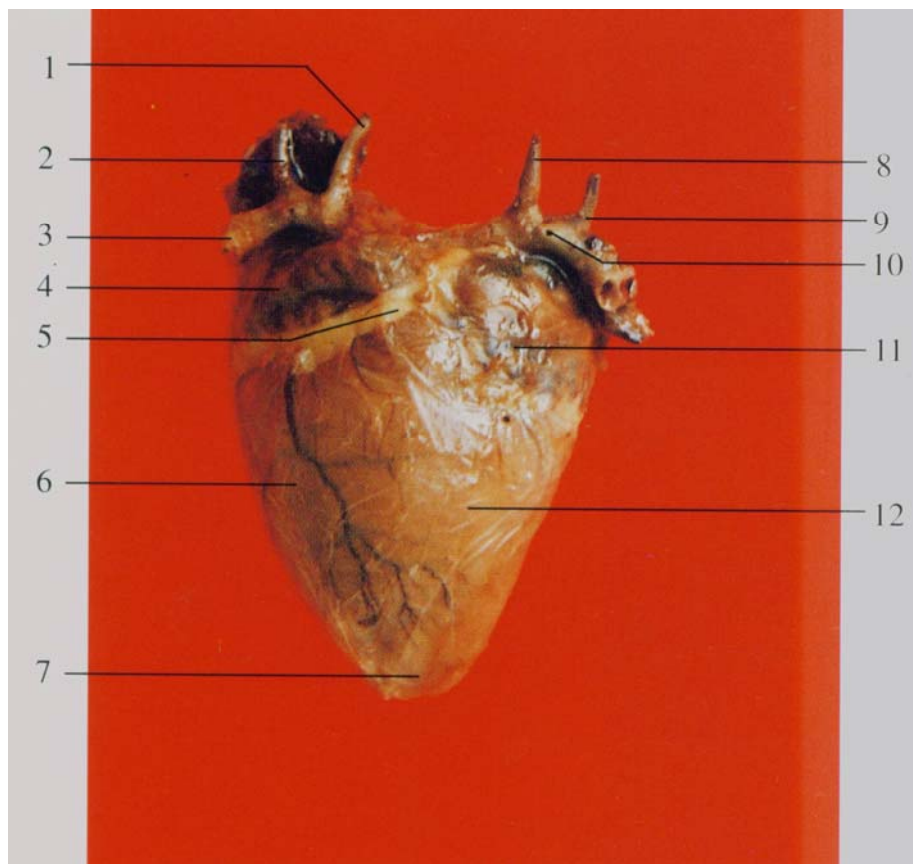


- 1 腹直肌 rectus abdominis muscle
- 2 股动、静脉 femoral artery. femoral vein
- 3 阴茎 penis
- 4 阴囊 scrotum
- 5 胸浅肌 pectoral superficialis muscle
- 6 腹外斜肌 external oblique muscle of abdomen
- 7 股直肌 rectus femoris muscle
- 8 股内侧肌 vastus medialis muscle
- 9 耻骨肌 pectineus muscle

- 10 长收肌 adductor longus muscle
- 11 股薄肌 gracilis muscle
- 12 半腱肌 semitendinous muscle
- 13 咬肌 masseter muscle
- 14 胸骨舌骨肌 sternohyoid muscle
- 15 胸乳突肌 sternomastoideus muscle
- 16 肩胛横肌 transverses scapulae muscle
- 17 胸腺 thymus
- 18 心 heart
- 19 肺 lung
- 20 膈 diaphragm
- 21 十二指肠 duodenum
- 22 空肠 jejunmn
- 23 膀胱 urinary bladder
- 24 二腹肌后腹 posterior belly of digastric muscle
- 25 脾 spleen
- 26 结肠 colon
- 27 回肠 ileum
- 28 股静脉 femoral vein
- 29 前列腺 prostate

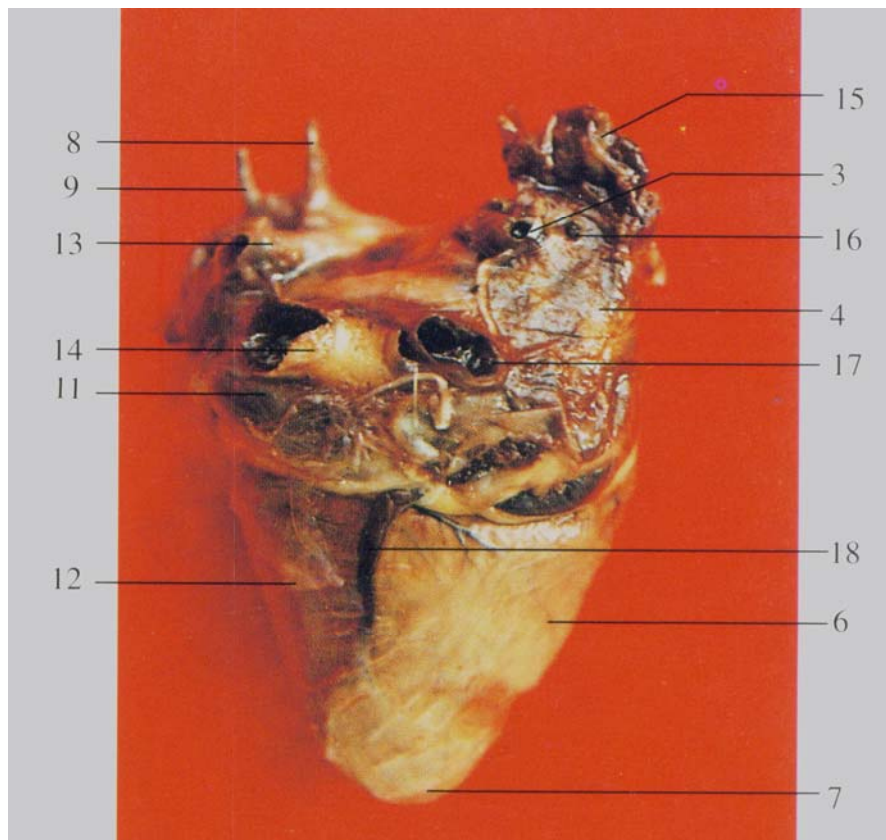


图VIII-29 心腹面 The heart. Ventral aspect



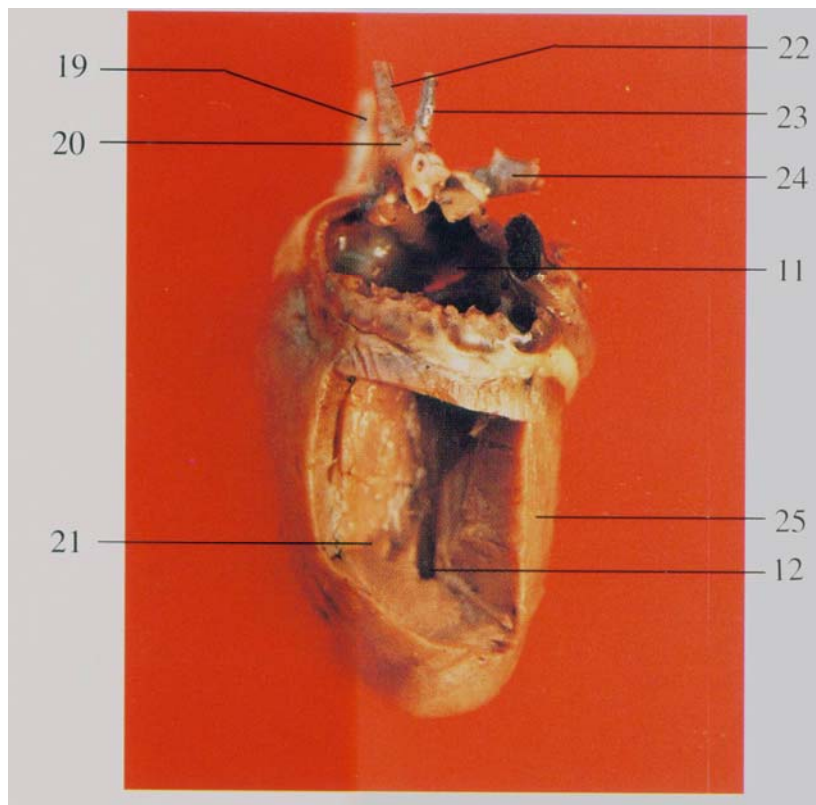
- 1 右颈内动脉 right internal carotid artery
- 2 右颈外动脉 right external carotid artery
- 3 右锁骨下动脉 right subclavian artery
- 4 右心房 right atrium
- 5 冠状沟 coronary sulcus
- 6 右心室 right ventricle
- 7 心尖 cardiac apex
- 8 左颈内动脉 left internal carotid artery
- 9 左颈外动脉 left external carotid artery
- 10 主动脉弓 aortic arch
- 11 左心房 left atrium
- 12 左心室 left ventricle

图VIII-30 心背面 The heart. Dorsal aspect



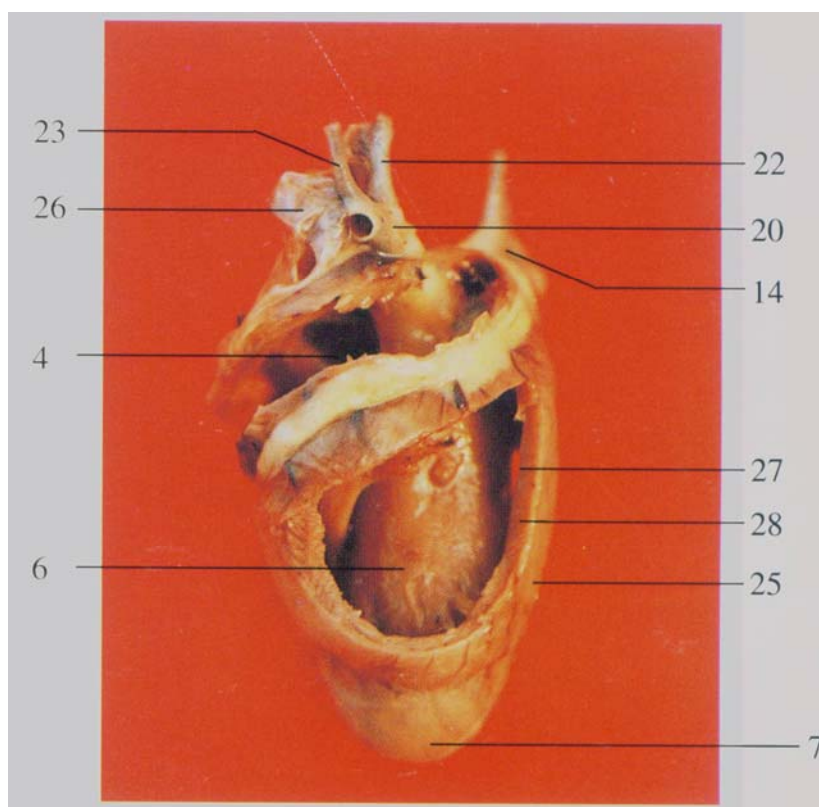
- 3 右锁骨下动脉 right subclavian artery
- 4 右心房 right atrium
- 5 冠状沟 coronary sulcus
- 6 右心室 right ventricle
- 7 心尖 cardiac apex
- 8 左颈内动脉 left internal carotid artery
- 9 左颈外动脉 left external carotid artery
- 10 主动脉弓 aortic arch
- 11 左心房 left atrium
- 12 左心室 left ventricle
- 13 肺动脉右支 right branch of pulmonary artery
- 14 肺静脉 pulmonary vein
- 15 前腔静脉 precaval vein
- 16 肺动脉左支 left branch of pulmonary artery
- 17 后腔静脉 postcaval vein

图VIII-31 左心房与左心室 The left atrium and left ventricle



- 11 左心房 left atrium
- 12 左心室 left ventricle
- 13 肺动脉右支 right branch of pulmonary artery
- 14 肺静脉 pulmonary vein
- 15 前腔静脉 precaval vein
- 16 肺动脉左支 left branch of pulmonary artery
- 17 后腔静脉 postcaval vein
- 18 心中静脉 middle cardiac vein
- 19 头臂动脉 brachiocephalic artery
- 20 主动脉弓 aortic arch
- 21 乳头肌 papillary muscles
- 22 左颈总动脉 left common carotid artery
- 23 左锁骨下动脉 left subclavian artery
- 24 右前腔静脉 right precaval vein
- 25 心外膜 extracardium

图VIII-32 右心房和右心室 The right atrium and right ventricle



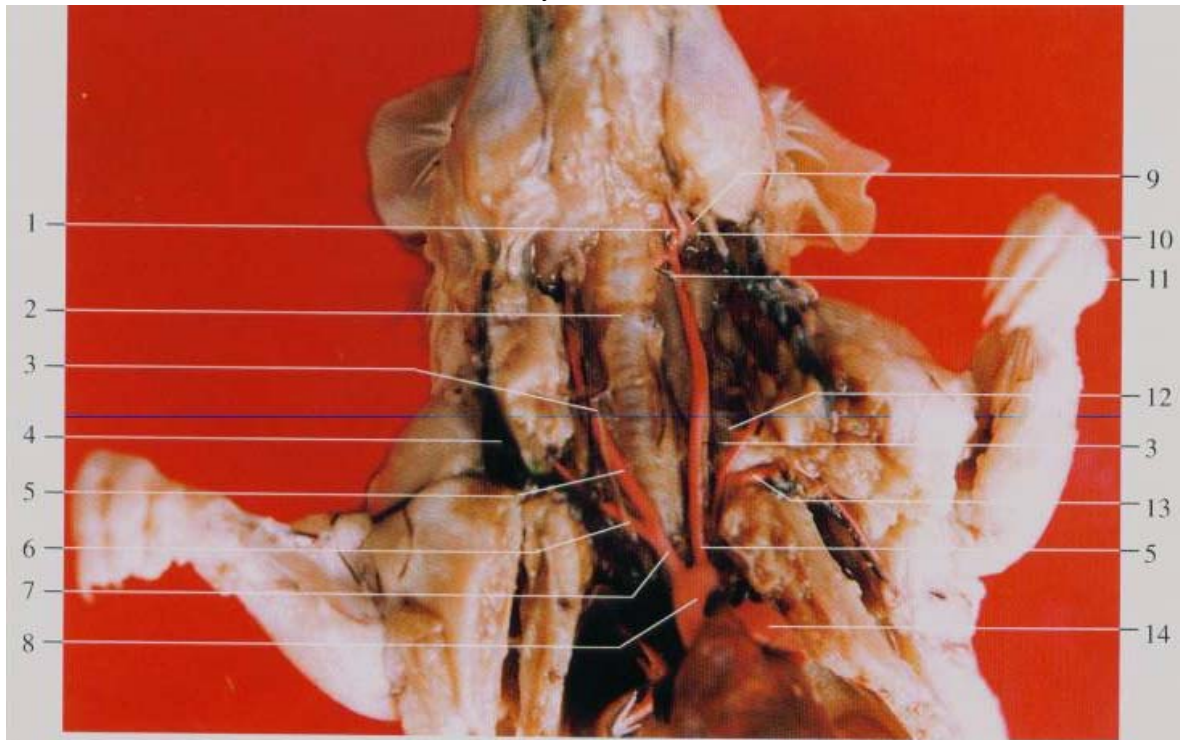
- 4 右心房 right atrium
- 5 冠状沟 coronary sulcus
- 6 右心室 right ventricle
- 7 心尖 cardiac apex
- 8 左颈内动脉 left internal carotid artery
- 9 左颈外动脉 left external carotid artery
- 10 主动脉弓 aortic arch
- 11 左心房 left atrium
- 12 左心室 left ventricle
- 13 肺动脉右支 right branch of pulmonary artery
- 14 肺静脉 pulmonary vein
- 15 前腔静脉 precaval vein
- 16 肺动脉左支 left branch of pulmonary artery
- 17 后腔静脉 postcaval vein
- 18 心中静脉 middle cardiac vein
- 19 头臂动脉 brachiocephalic artery
- 20 主动脉弓 aortic arch
- 21 乳头肌 papillary muscles
- 22 左颈总动脉 left common carotid artery
- 23 左锁骨下动脉 left subclavian artery
- 24 右前腔静脉 right precaval vein
- 25 心外膜 extracardium

26 肺动脉 pulmonary artery

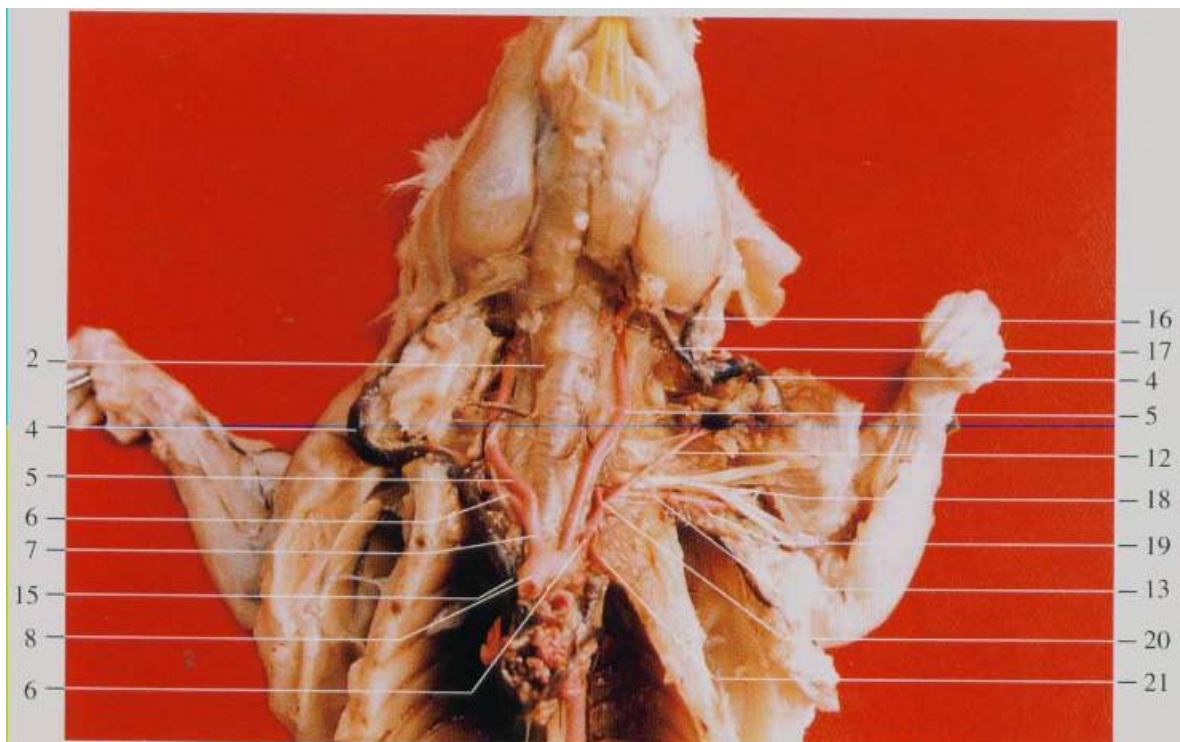
27 心内膜 endocardium

28 心肌层 myocardium

图VIII-33 颈总动脉 The common carotid artery



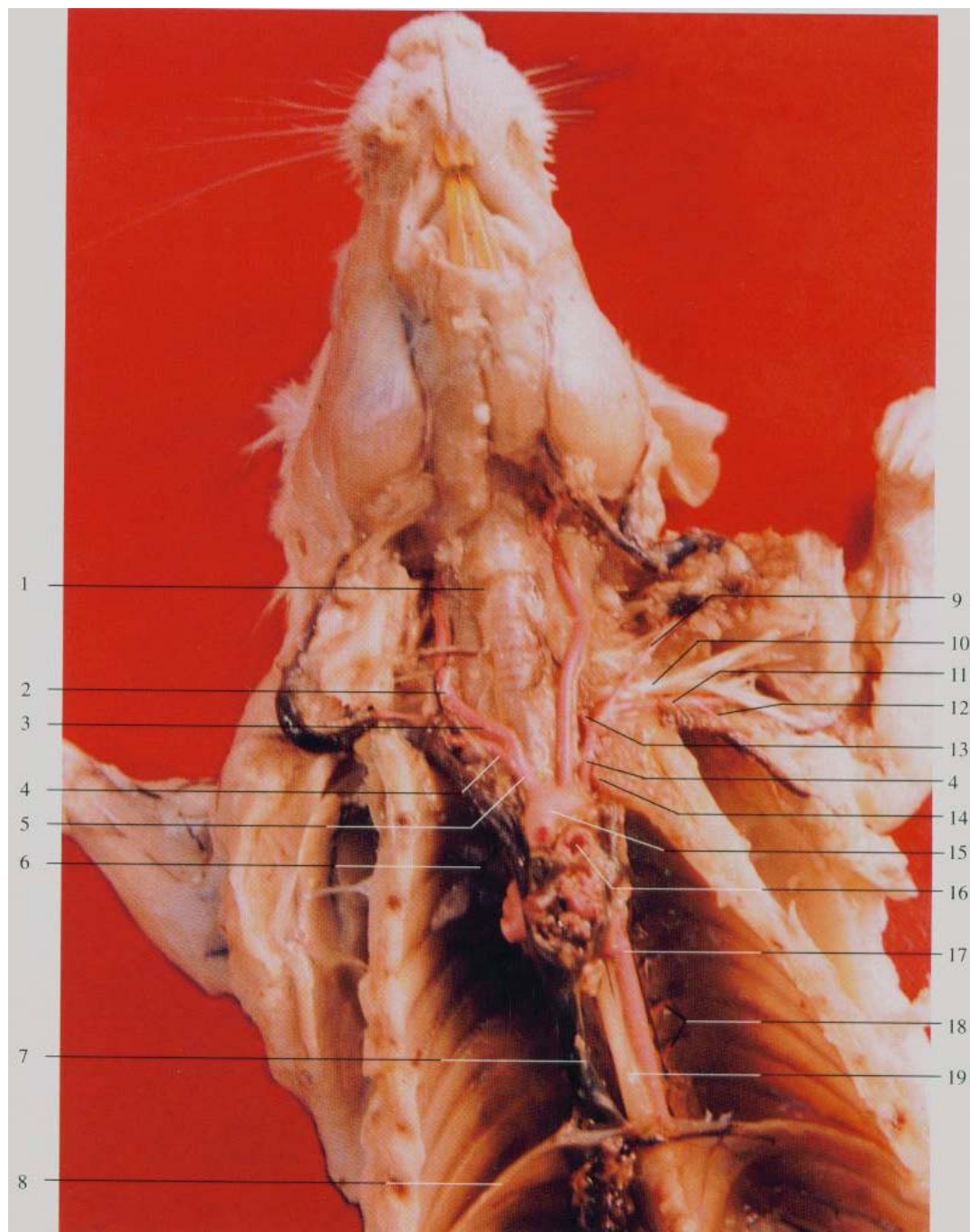
图VIII-34 主动脉弓 The aorta arch



- 1 舌动脉 lingual artery
- 2 甲状腺 thyroid gland
- 3 迷走交感神经链 vagosympathetic chain
- 4 颈外静脉 external jugular vein

- 5 颈总动脉 common carotid artery
- 6 锁骨下动脉 subclavian artery
- 7 无名动脉 anonyma artery
- 8 主动脉弓 aorta arch
- 9 颌外动脉 external maxillary artery
- 10 耳前动脉 anterior auricular artery
- 11 甲状腺上动脉 superior thyroid artery
- 12 颈动脉干 carotiq trunk
- 13 腋动脉 axillary artery
- 14 左心耳 left auricle
- 15 前腔静脉 precaval vein
- 16 面后静脉 posterior facial vein
- 17 面前静脉 anterior facial vein
- 18 臂神经丛 brachial plexus
- 19 胸外侧动脉 external thoracicartery
- 20 椎动脉 vertebral artery
- 21 肋颈动脉干 costocervicaltrunk

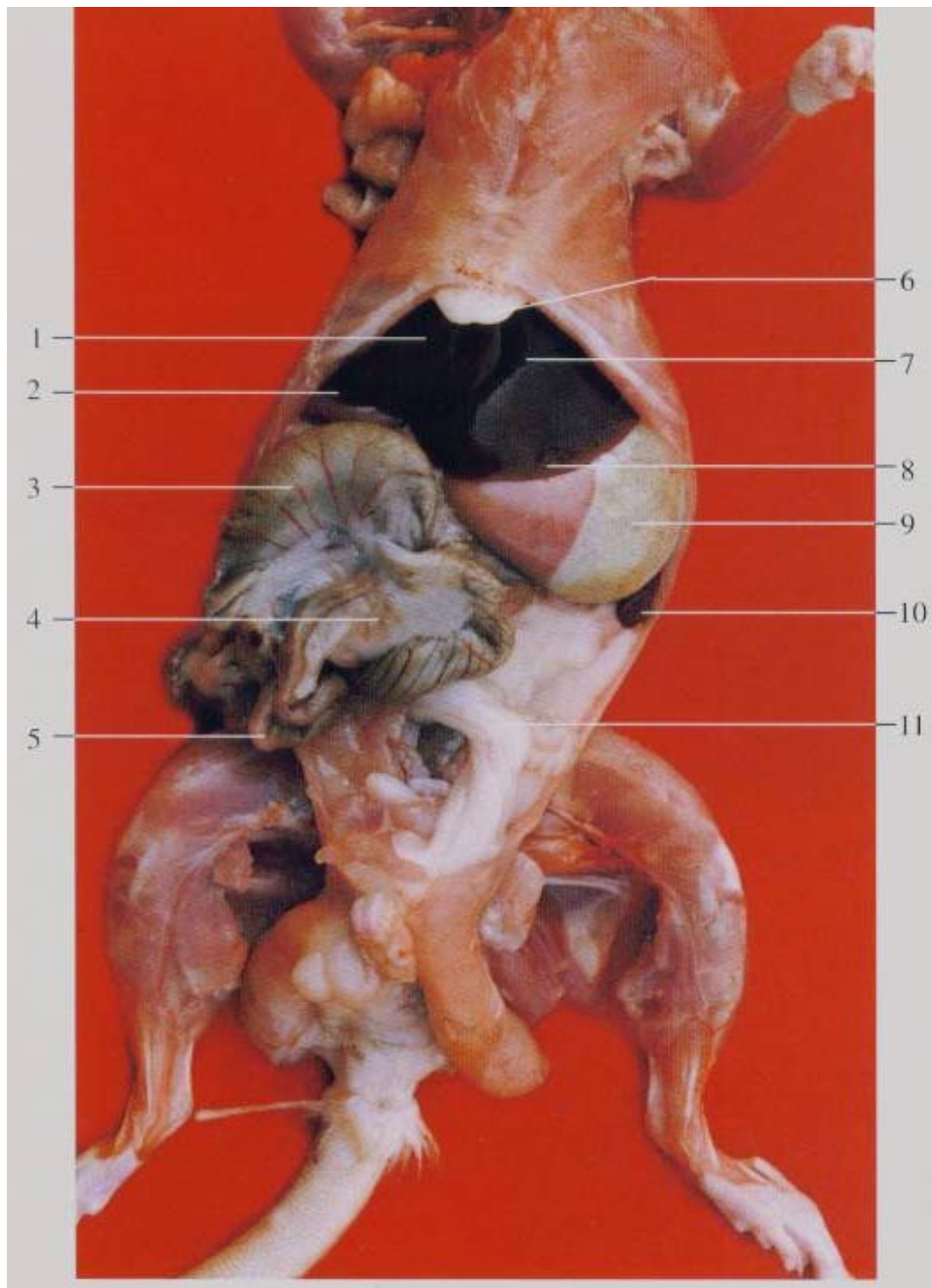图VIII-35 胸主动脉 The thoracic aorta



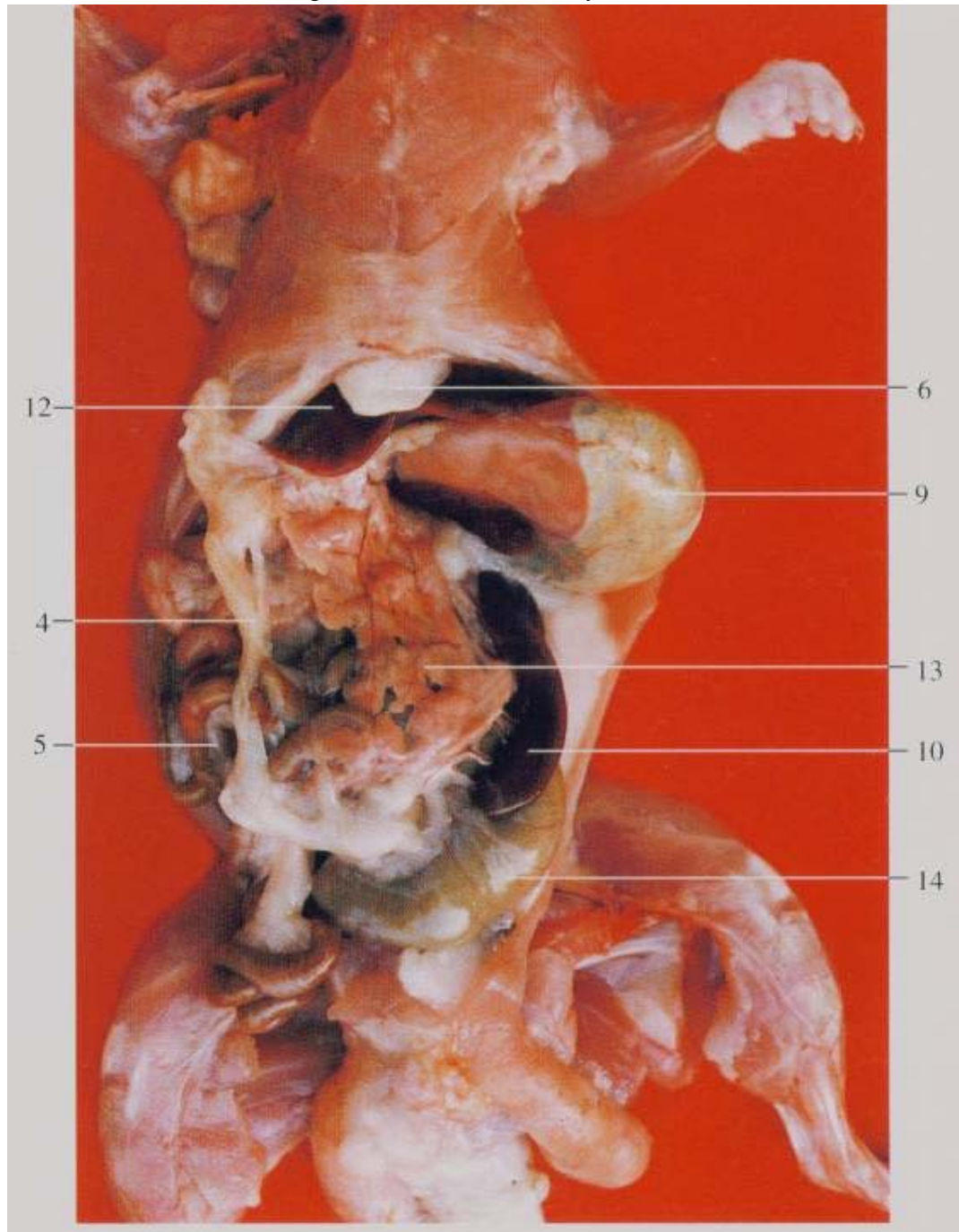- |                              |                                  |
|------------------------------|----------------------------------|
| 1 甲状腺 thyroid gland          | 2 迷走交感神经链 vagosympathetic chain  |
| 3 颈总动脉 common carotid artery | 4 锁骨下动脉 subclavian artery        |
| 5 无名动脉 innominate artery     | 6 前腔静脉 precaval vein             |
| 7 后腔静脉 postcaval vein        | 8 膈 diaphragm                    |
| 9 颈动脉干 carotid trunk         | 10 臂神经丛 brachial plexus          |
| 11 腋动脉 axillary artery       | 12 胸外侧动脉 lateral thoracic artery |
| 13 椎动脉 vertebral artery      | 14 肋颈动脉干 costocervical trunk     |
| 15 主动脉弓 aorta arch           | 16 肺动脉 pulmonary artery          |
| 17 胸主动脉 thoracic aorta       | 18 肋间动脉 intercostal artery       |
| 19 食管 esophagus              |                                  |



图VIII-37 腹腔器官 (2) The organs in the abdominal cavity (2)



图VIII-38 腹腔器官 (3)The organs in the abdominal cavity (3)



1 肝右中叶 right middle lobe of liver

3 横结肠 transverse colon

5 空肠 jejunum

7 肝左中叶 left middle lobe of liver

9 胃 stomach

11 脂肪 fat

13 胰 pancreas

2 肝右外叶 right lateral lobe of liver

4 大网膜 greater omentum

6 剑突 xiphoid process

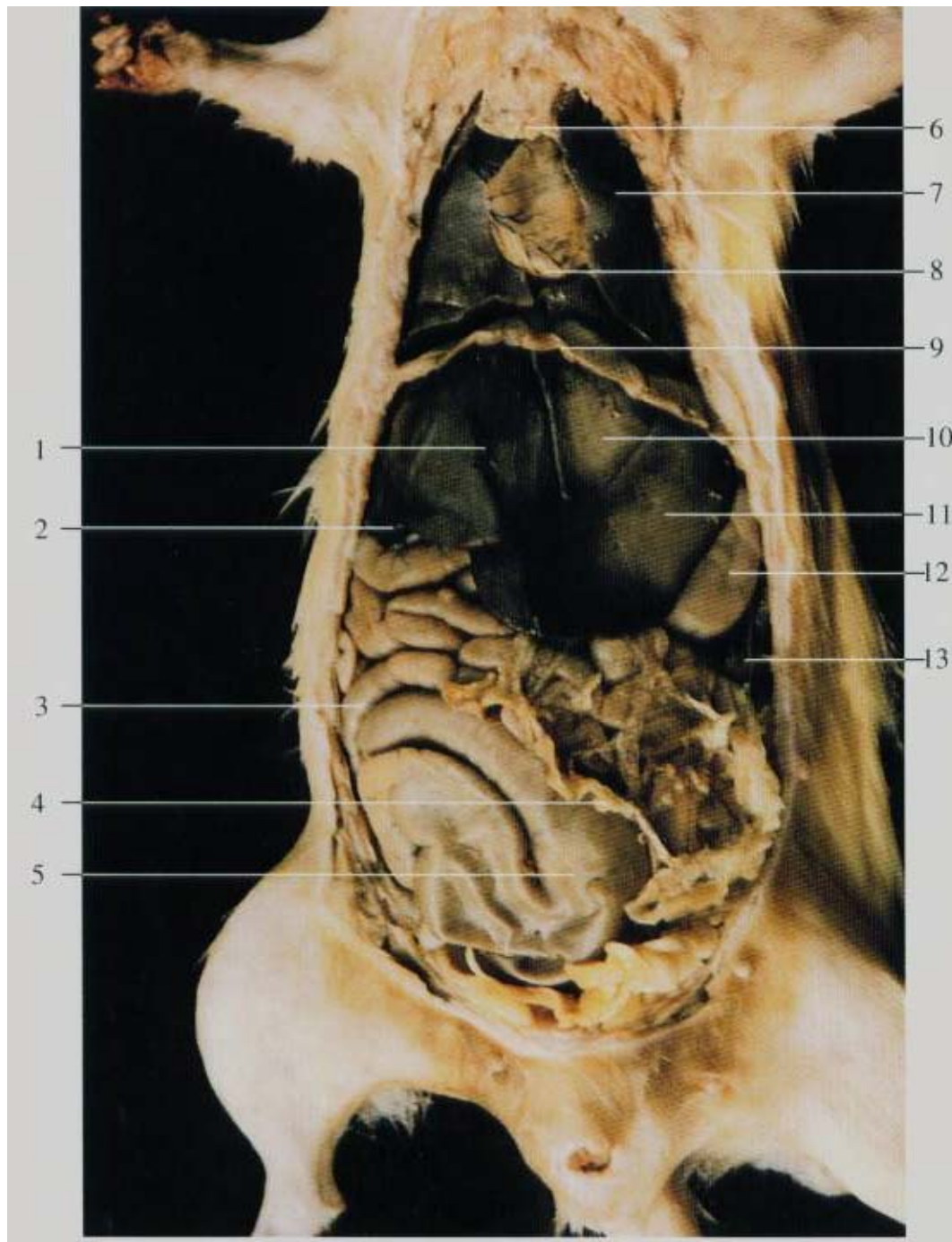
8 肝左外叶 left lateral lobe of liver

10 脾 spleen

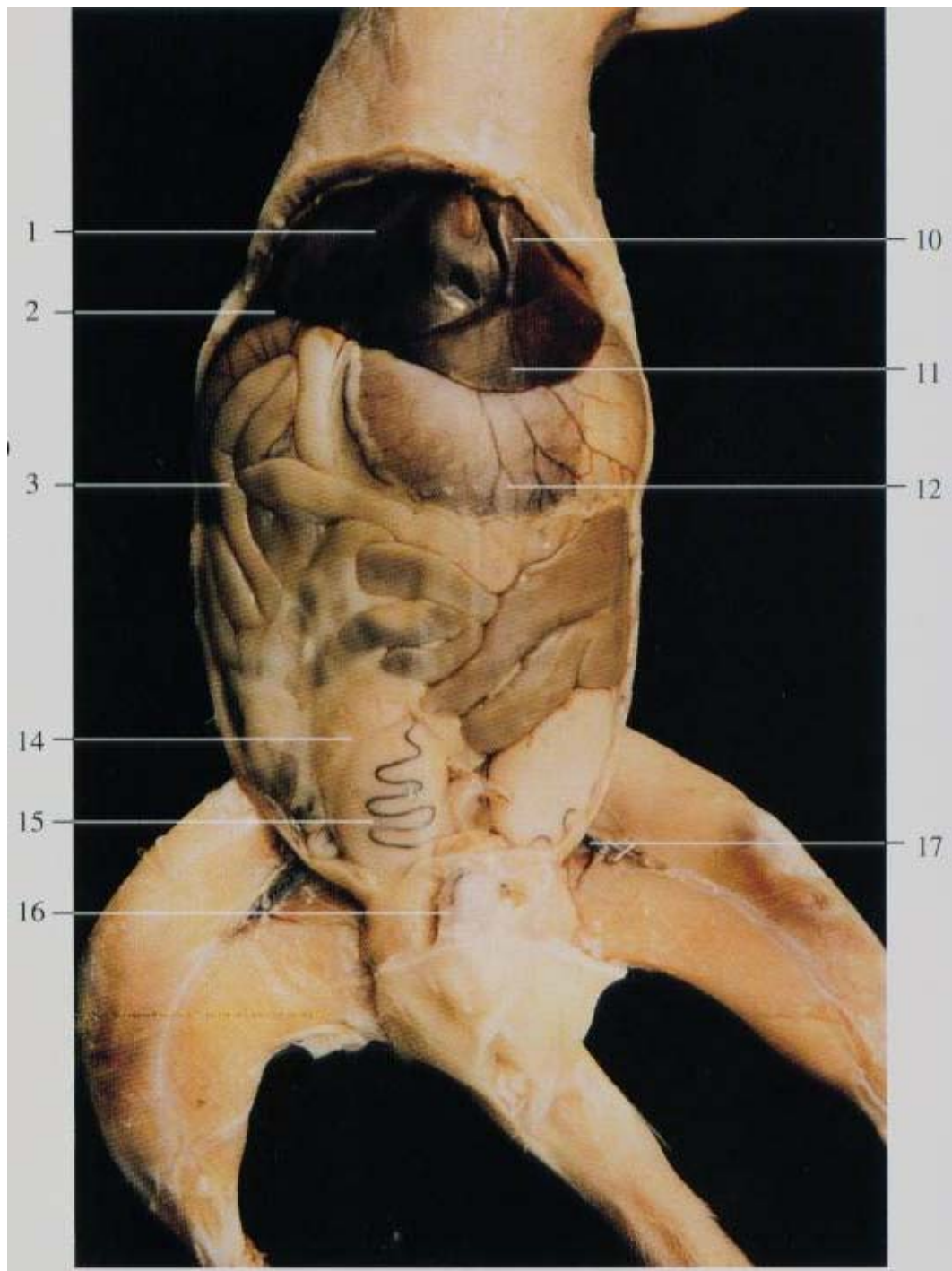12 肝 liver

14 结肠 colon

图VIII-39 腹腔器官 (4) The organs in the abdominal cavity (4)



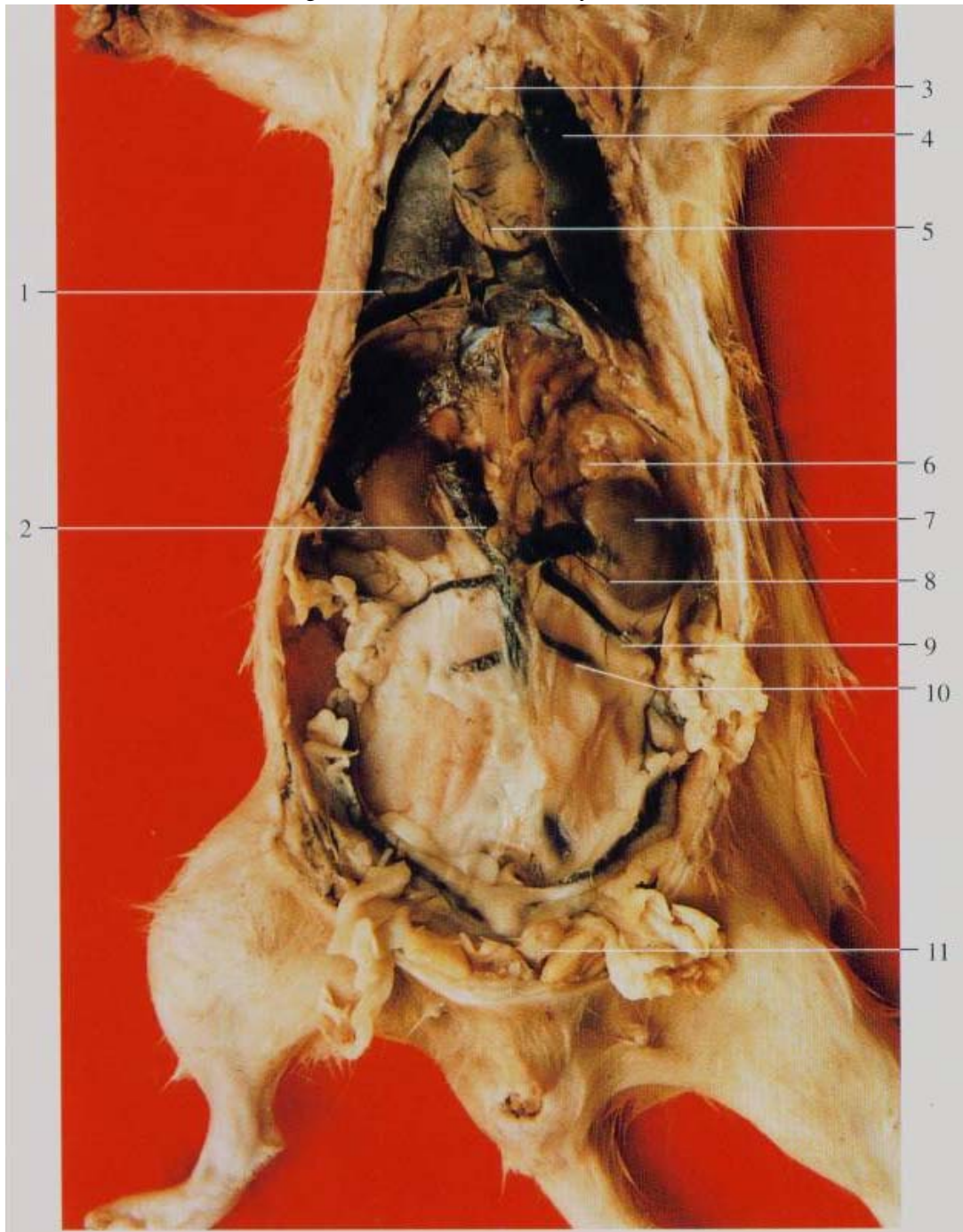图VIII-40 腹腔器官 (5) The organs in the abdominal cavity (5)



- 1 肝右中叶 right middle lobe of liver
- 3 小肠 small intestine
- 5 结肠 colon
- 7 肺 lung
- 9 膈 diaphragm
- 11 肝左外叶 left lateral lobe of liver
- 13 脾 spleen
- 15 睾丸 testis
- 17 股动、静脉 femoral artery and vein

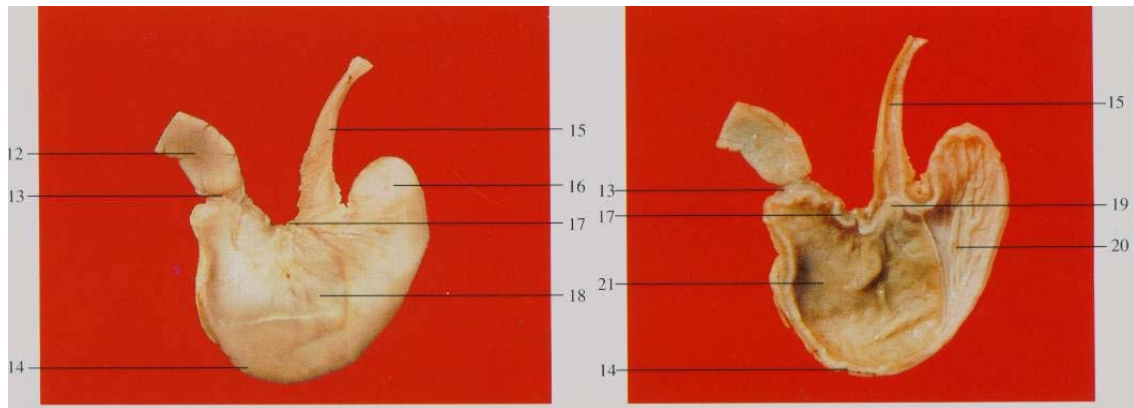
- 2 肝右外叶 right lateral lobe of liver
- 4 大网膜 greater omentum
- 6 胸腺 thymus
- 8 心 heart
- 10 肝左中叶 left middle lobe of liver
- 12 胃 stomach
- 14 附睾 epididymis
- 16 阴茎 penis

图VIII-41 腹腔器官 (6)The organs in the abdominal cavity (6)



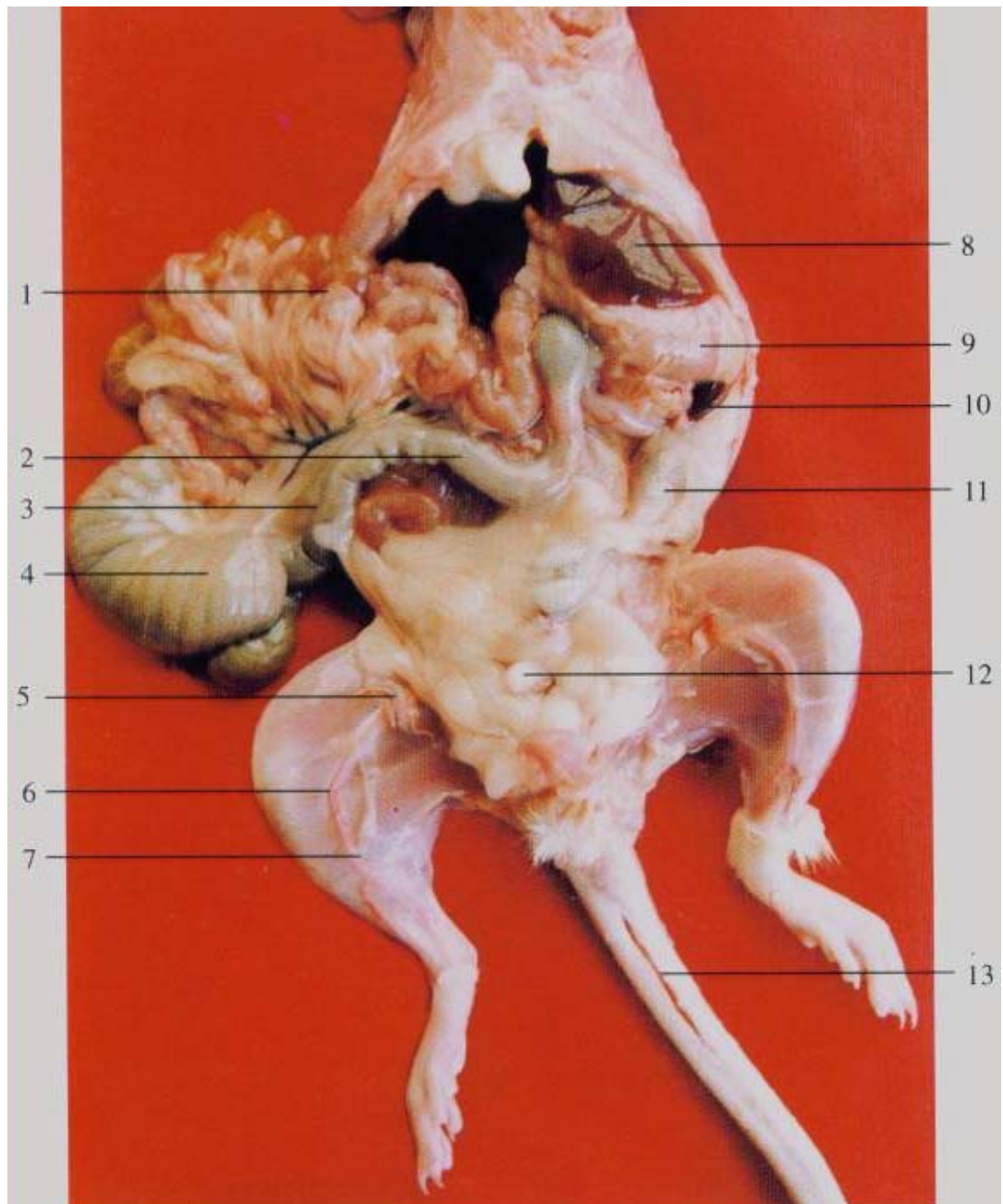
图VIII-42 胃 The stomach

图VIII-43 胃壁内面 The wall of stomach. Inner surface

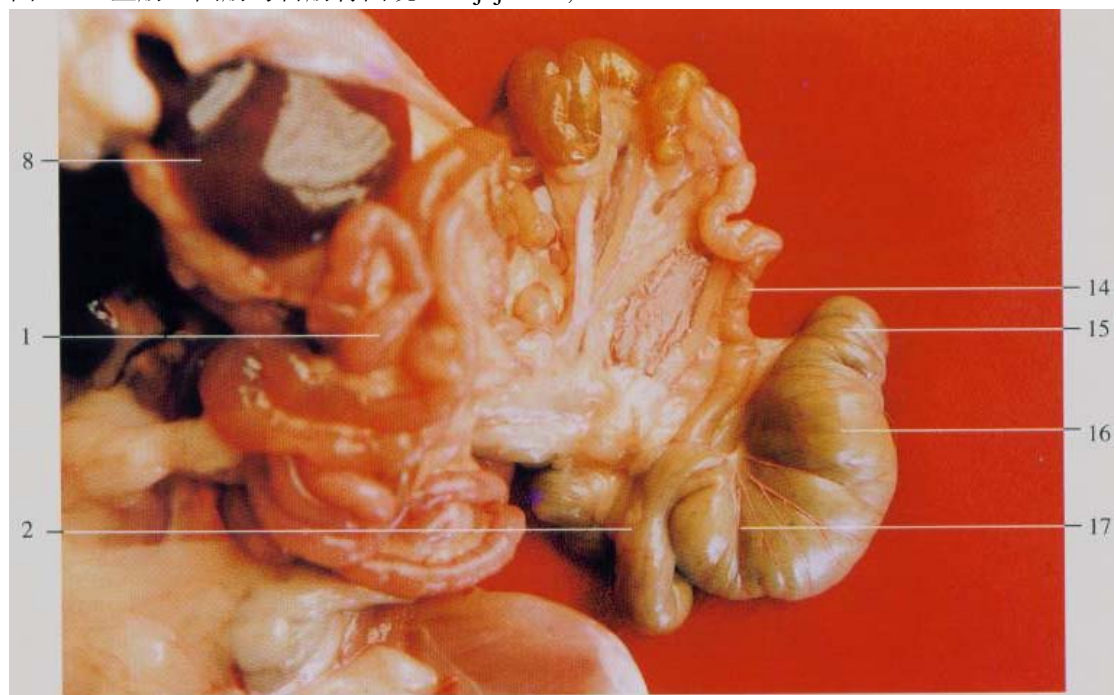


- 1 膈 diaphragm
- 2 前腔静脉 precaval vein
- 3 胸腺 thymus
- 4 肺 lung
- 5 心 heart
- 6 肾上腺 adrenal gland
- 7 肾 kidney
- 8 肾门静脉 renal portal vein
- 9 精索内静脉 internal spermatic vein
- 10 髂腰静脉 iliolumbar vein
- 11 膀胱 urinary bladder
- 12 十二指肠 duodenum
- 13 幽门 pylorus
- 14 胃大弯 greater curvature of stomach
- 15 食管 esophagus
- 16 胃底 fundus of stomach
- 17 胃小弯 lesser curvature of stomach
- 18 胃体 body of stomach
- 19 贲门 pylorus
- 20 胃粘膜皮区 cutaneous part of gastric mucous
- 21 胃粘膜腺区 glandular part of gastric mucous

图VIII-44 空肠、回肠与盲肠腹面观 The jejunum, ileum and cecum. Ventral view



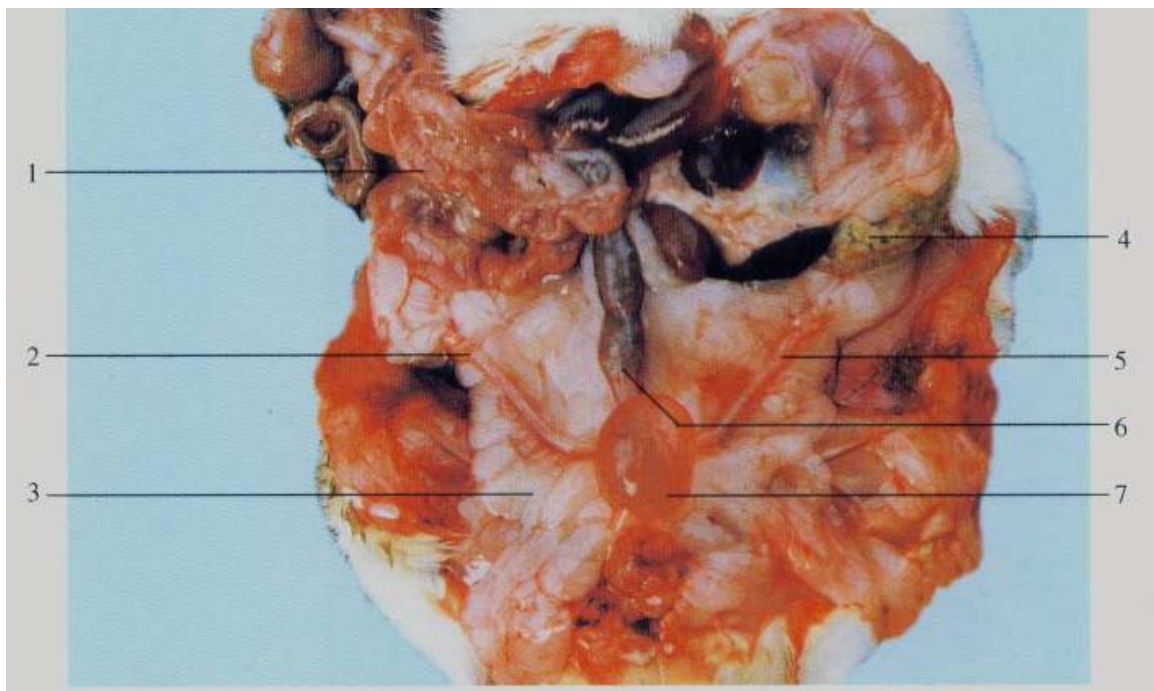
图VIII-45 空肠、回肠与盲肠背面观 The jejunum, ileum and cecum. Dorsal view



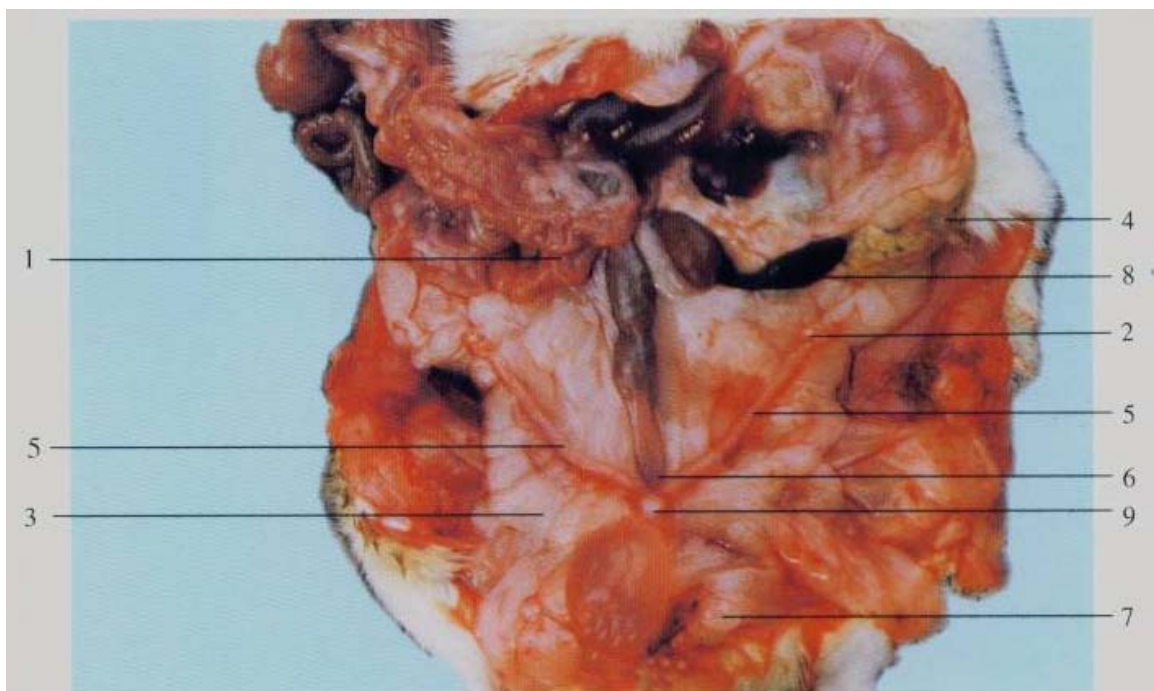
- 1 空肠 jejunum
- 2 横结肠 transverse colon
- 3 升结肠 ascending colon
- 4 盲肠 cecum
- 5 腹壁浅动脉 superficial epigastric artery
- 6 隐动脉 saphenous artery
- 7 隐大静脉 great saphenous vein
- 8 肝 liver
- 9 胃 stomach
- 10 脾 spleen
- 11 降结肠 descending colon
- 12 膀胱 urinary bladder
- 13 尾中动脉 middle coccygeal artery
- 14 回肠 ileum
- 15 盲肠尖 apex of cecum
- 16 盲肠体 body of cecum
- 17 盲肠基部 base of cecum



图VIII-46 生殖器官（♀）（1） The genital organs（♀）（1）



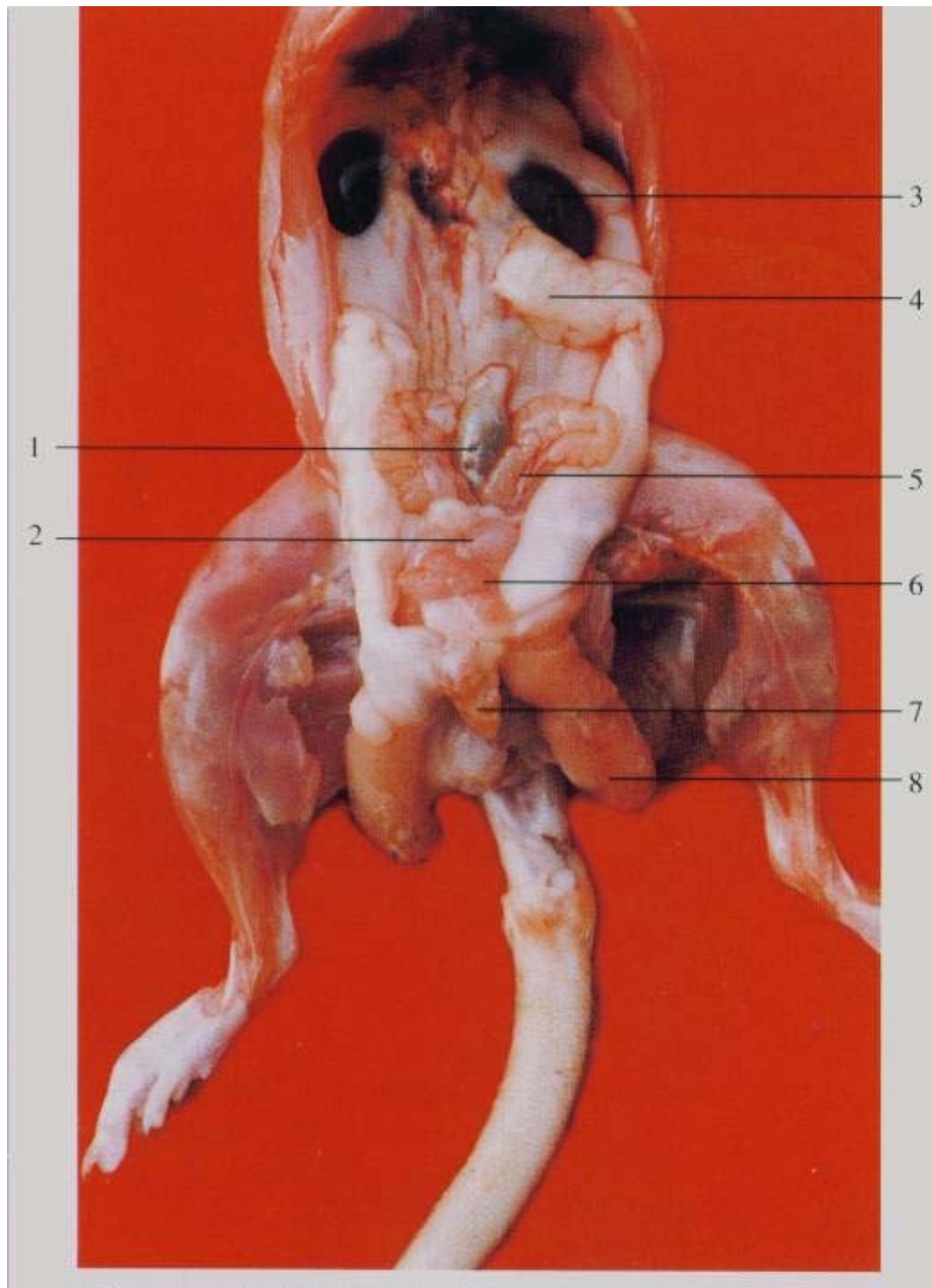
图VIII-47 生殖器官（♀）（2）The genital organs（♀）（2）



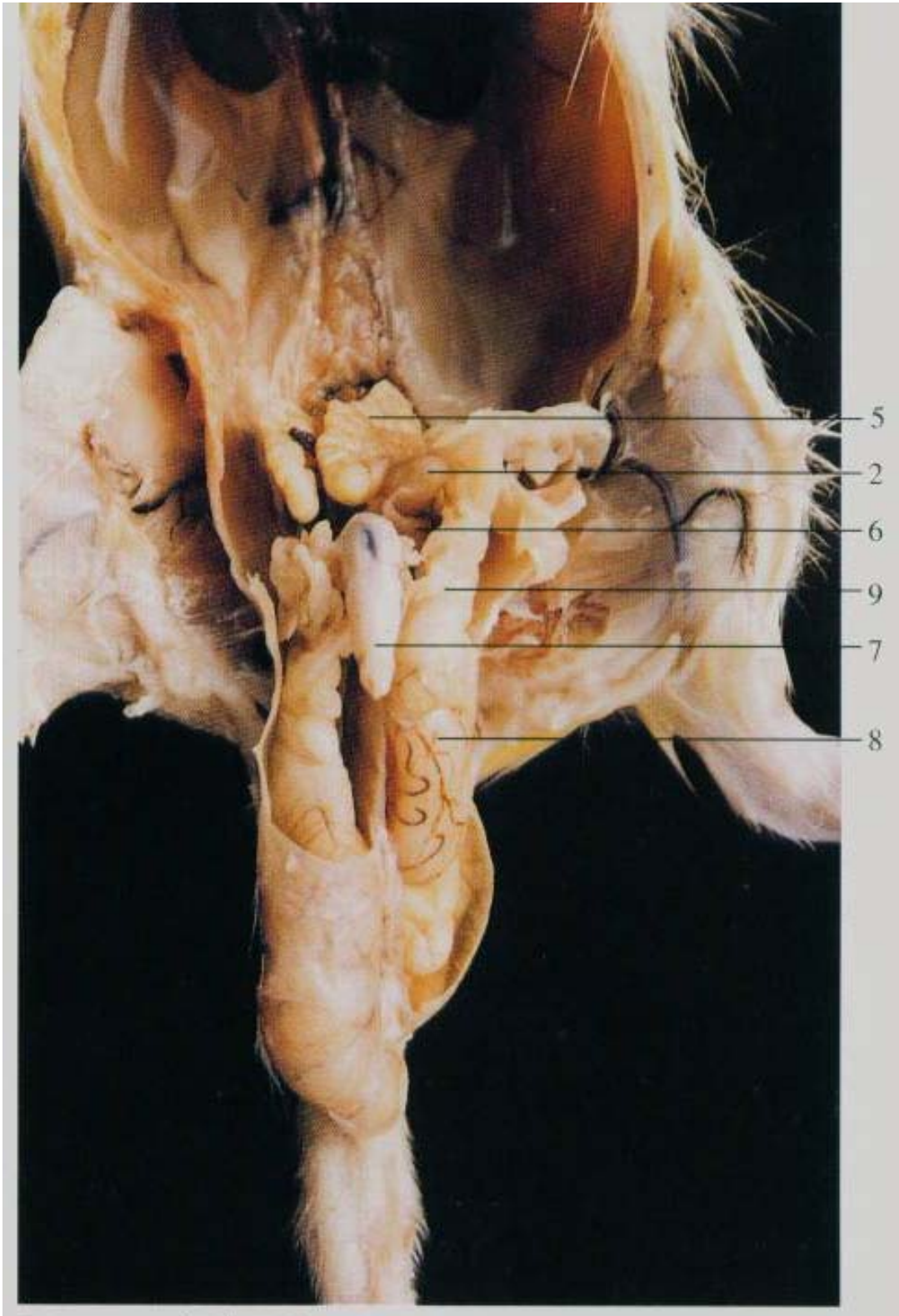
1 小肠 small intestine  
3 脂肪 fat  
5 子宫角 horn of uterus  
7 膀胱 urinary bladder  
9 子宫体 body of uterus

2 输卵管 uterine tube  
4 胃 stomach  
6 直肠 rectum  
8 脾 spleen

图VIII-50 生殖器官 (♂) (3) The genital organs (♂) (3)



图VIII-51 生殖器官 (♂) (4)The genital organs (♂) (4)



1 直肠 rectum

3 肾 kidney

5 精囊 seminal vesicle

7 阴茎 penis

9 精索 spermatic cord

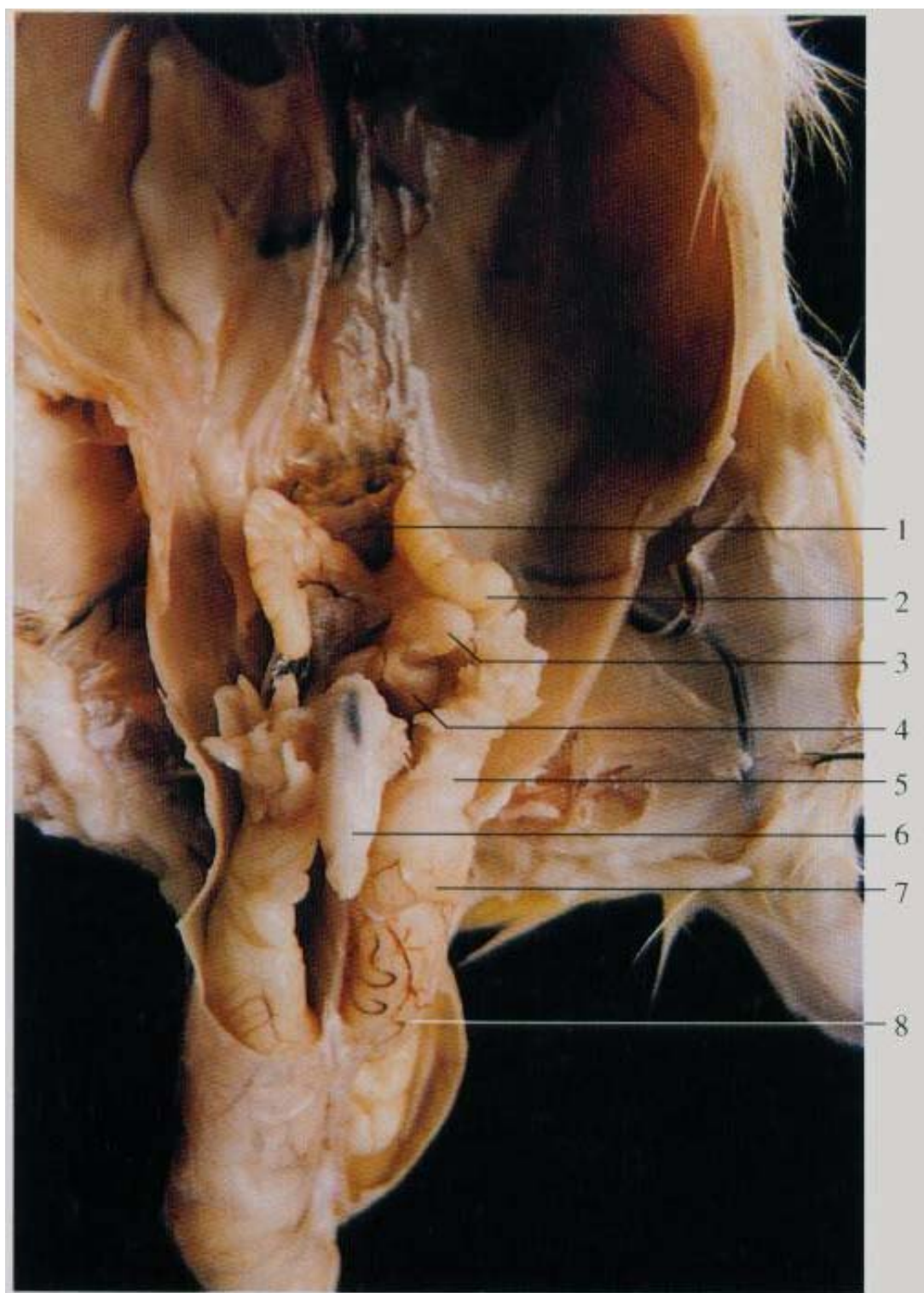
2 膀胱 urinary bladder

4 脂肪 fat

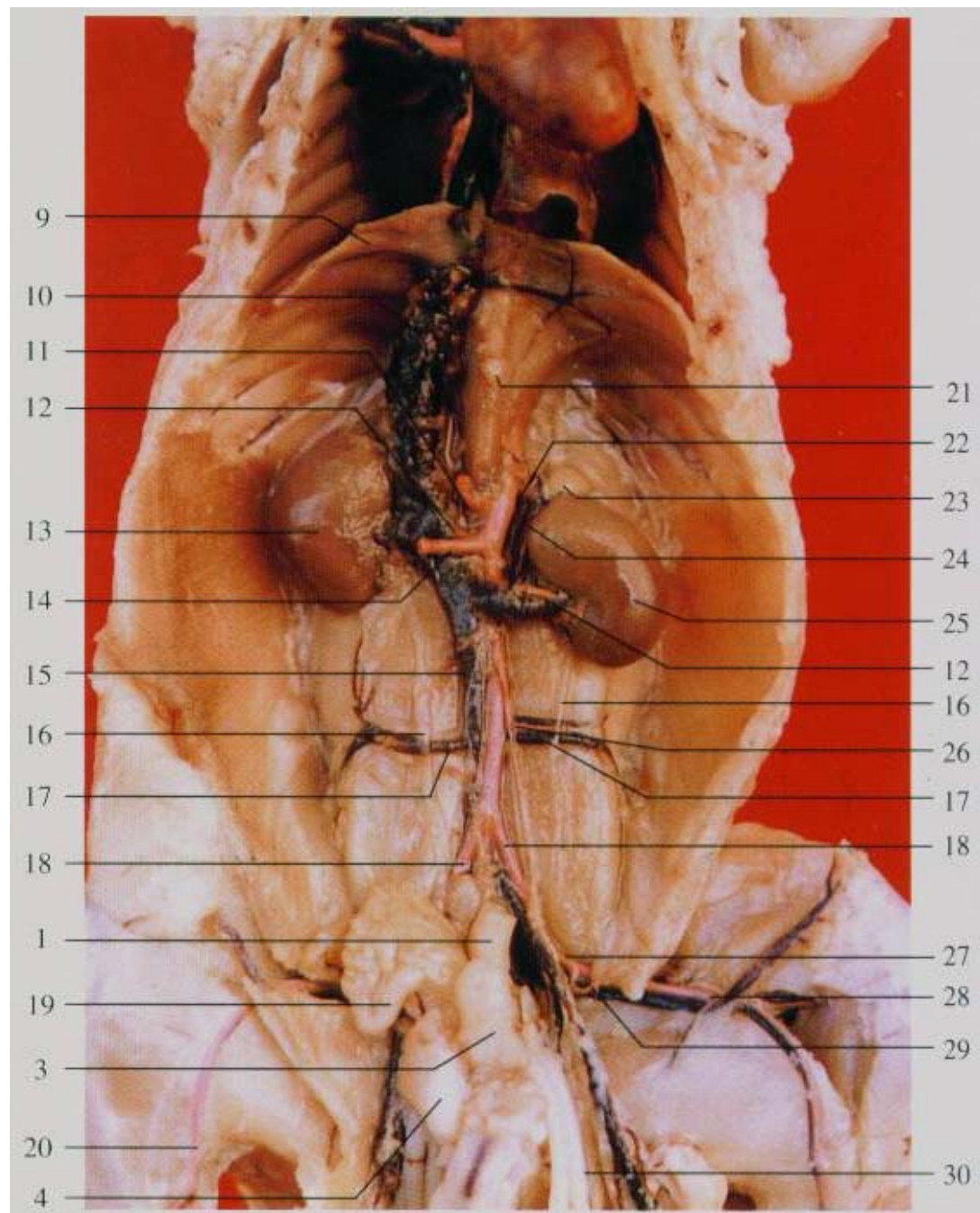6 前列腺 prostate

8 附睾 epididymis

图VIII-52 生殖器官 (♂) (5) The genital organs (♂) (5)



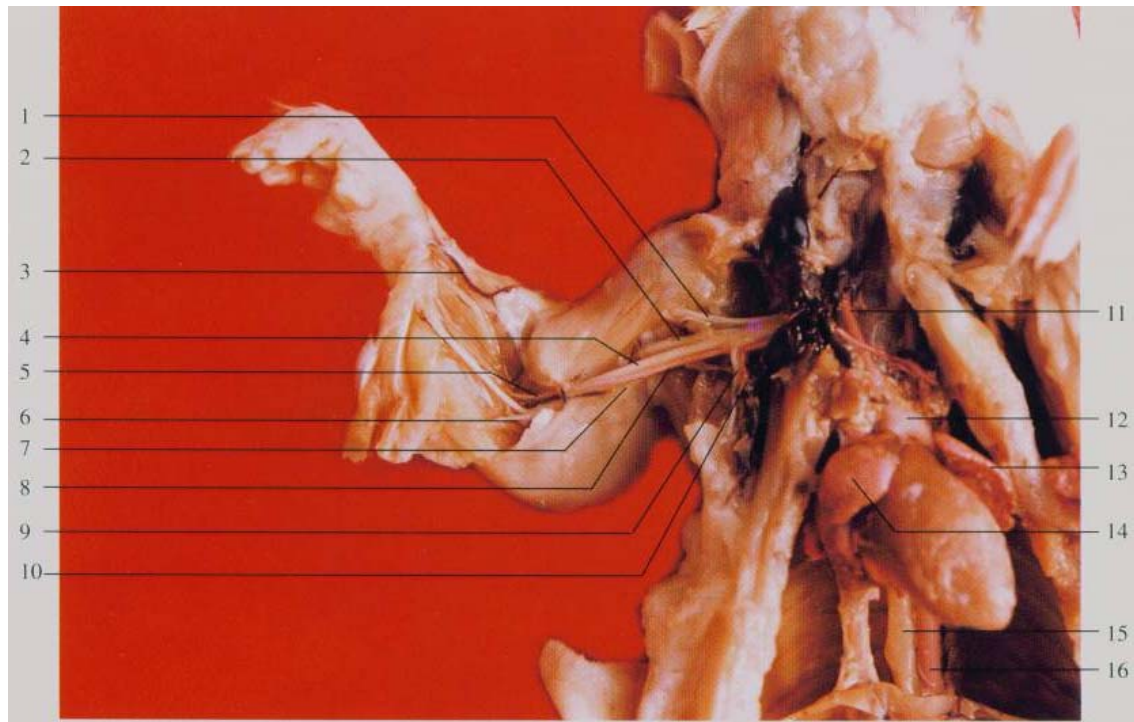
图VIII-53 腹主动脉及其分支 The abdominal aorta and branches



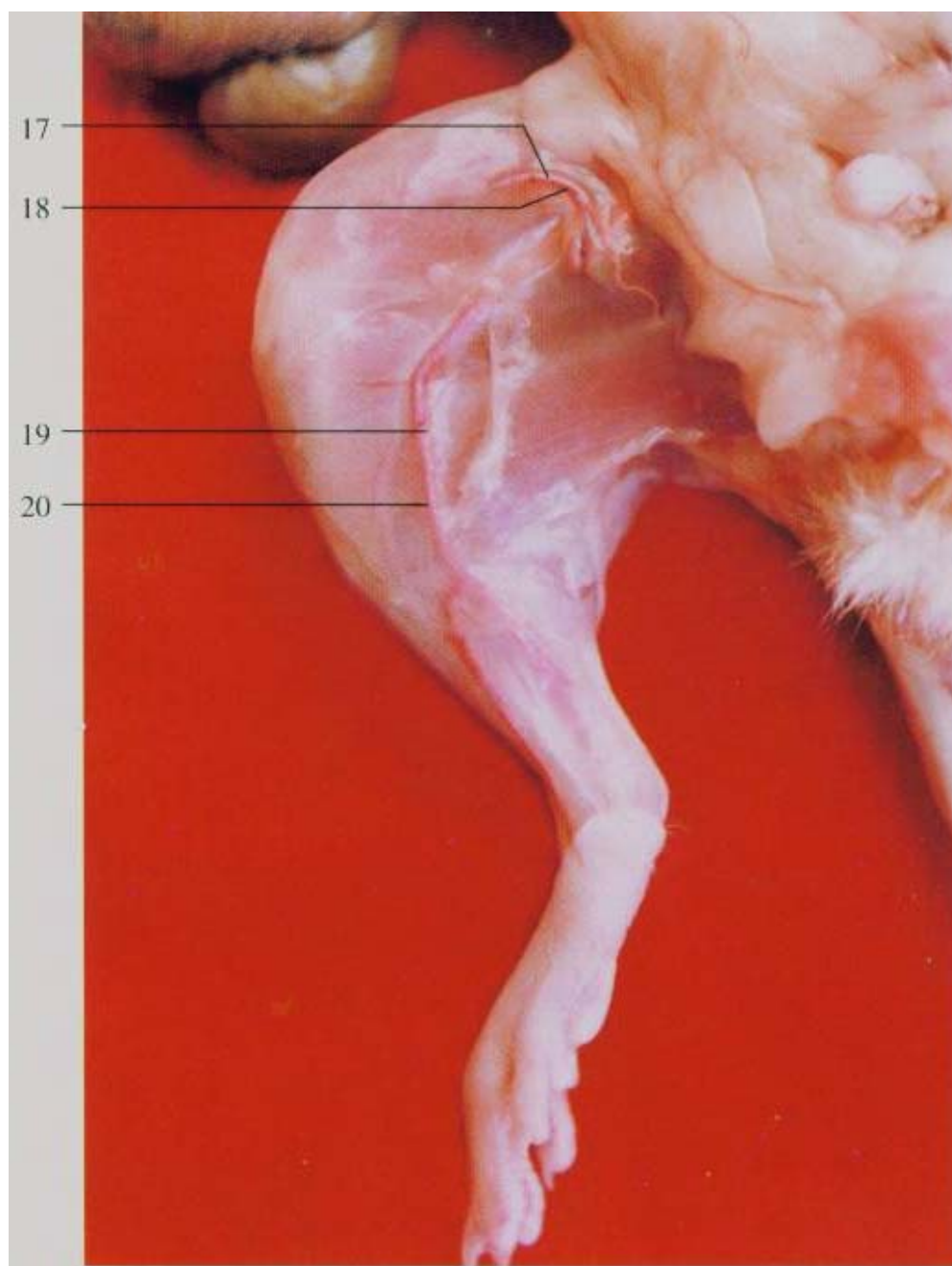- 1 直肠 rectum
- 2 精囊 seminal vesicle
- 3 膀胱 urinary bladder
- 4 前列腺 prostate
- 5 精索 spermatic cord
- 6 阴茎 penis
- 7 附睾 epididymis
- 8 睾丸 testis
- 9 膈 diaphragm
- 10 后腔静脉 postcaval vein
- 11 腹腔动脉 celiac artery

- 12 肾动脉 renal artery
- 13 右肾 right kidney
- 14 前肠系膜动脉 anterior mesenteric artery
- 15 精索内动脉 internal spermatic artery
- 16 输尿管 ureter
- 17 髂腰动、静脉 iliolumbar artery and vein
- 18 髂总动脉 common iliac artery
- 19 贮精囊 vesicula seminalis
- 20 隐动脉 saphenous artery
- 21 食管 esophagus
- 22 膈下动脉 inferior phrenic artery
- 23 肾上腺 adrenal glands
- 24 肾上腺上动脉 superior adrenal artery
- 25 左肾 left kidney
- 26 后肠系膜动脉 posterior mesenteric artery
- 27 髂外动脉 external iliac artery
- 28 股动脉 femoral artery
- 29 腹壁阴部动脉干 arterial epigastro-pudendal trunk
- 30 输精管 ductus deferens

图VIII-56 前肢内侧面 The anterior limb. Medial aspect



图VIII-57 后肢内侧面(1)The posterior limb. Medial aspect (1)

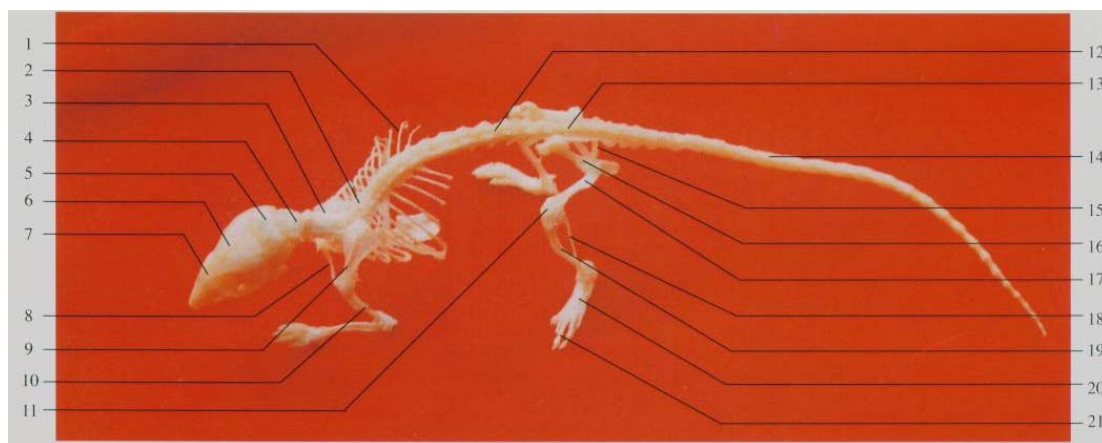


1 腋神经 axillary nerve  
3 头静脉 cephalic vein  
5 正中动脉 median artery  
7 尺神经 ulnar nerve  
9 胸长神经 long thoracic nerve  
11 颈总动脉 common carotid artery  
13 左心耳 left auricle  
15 食管 esophagus  
17 腹壁浅动脉 superficial epigastric artery  
19 隐动脉 saphenous artery

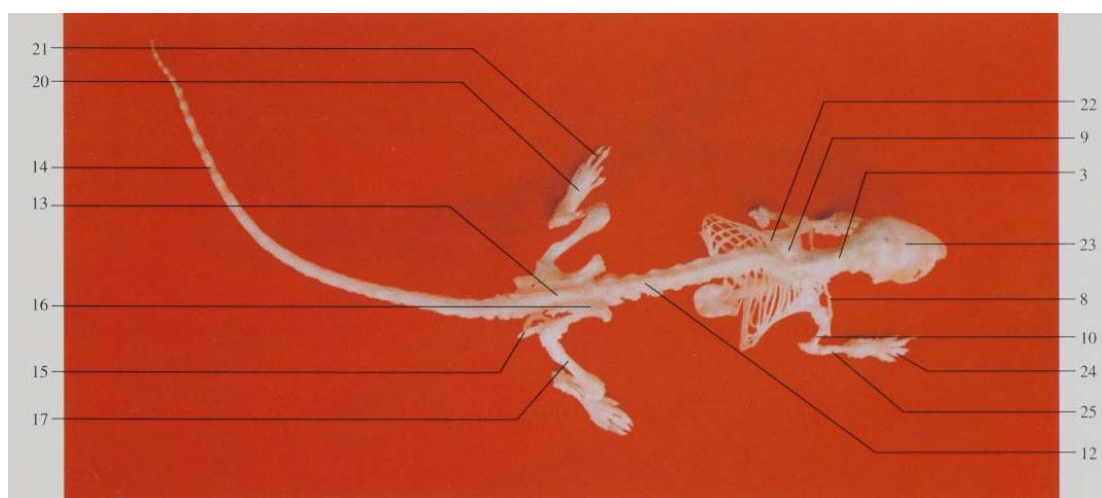
2 桡神经 radial nerve  
4 正中神经 median nerve  
6 肌支 muscular branch  
8 臂动脉 brachial artery  
10 胸外侧动脉 external thoracic artery  
12 主动脉弓 aorta arch  
14 右心耳 right auricle  
16 胸主动脉 thoracic aorta  
18 腹壁浅静脉 superficial epigastric vein  
20 隐大静脉 great saphenous vein



图IX-1 整体骨骼侧面观 The skeleton. Lateral view

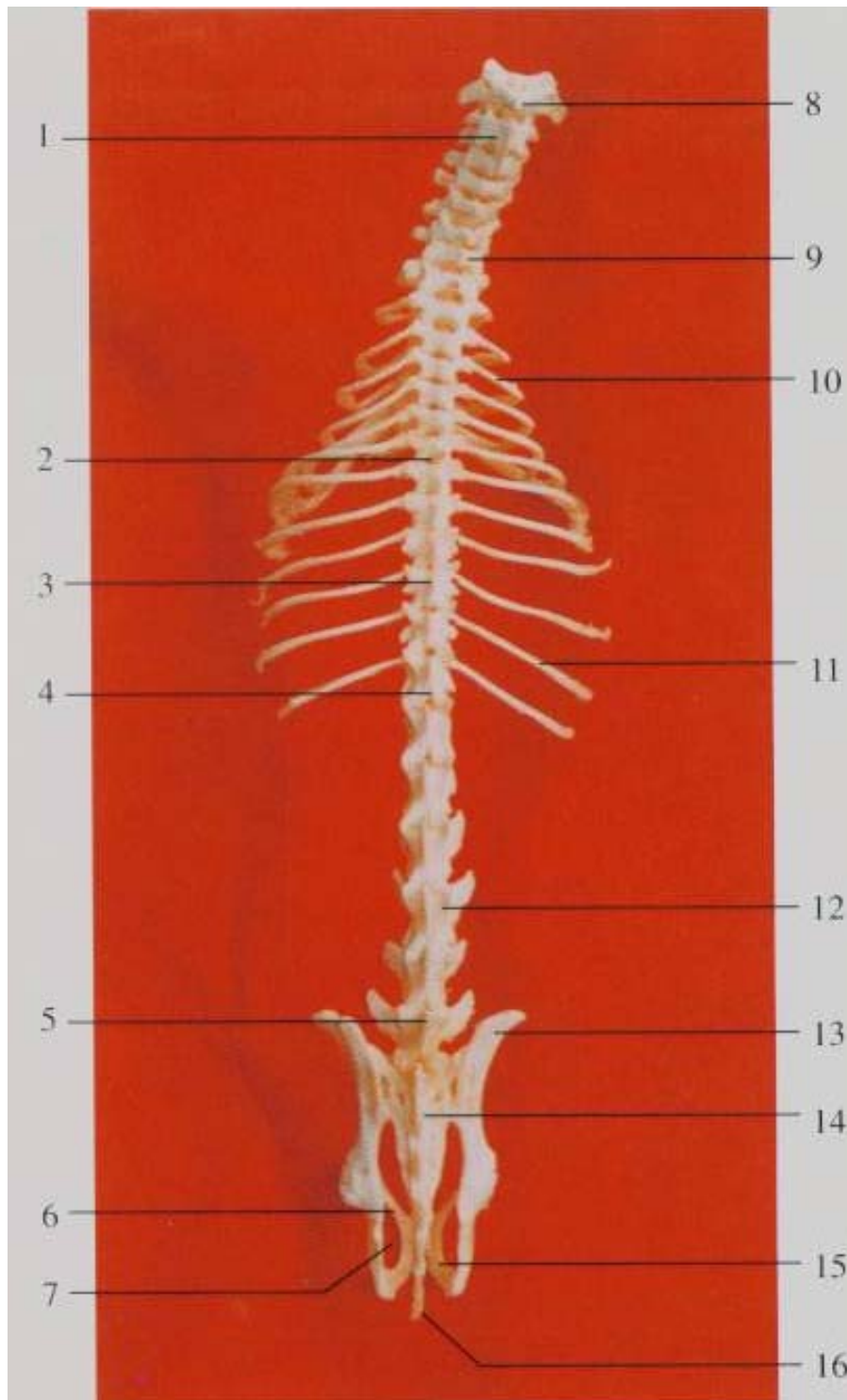


图IX-2 整体骨骼背面观 The skeleton. Dorsal view

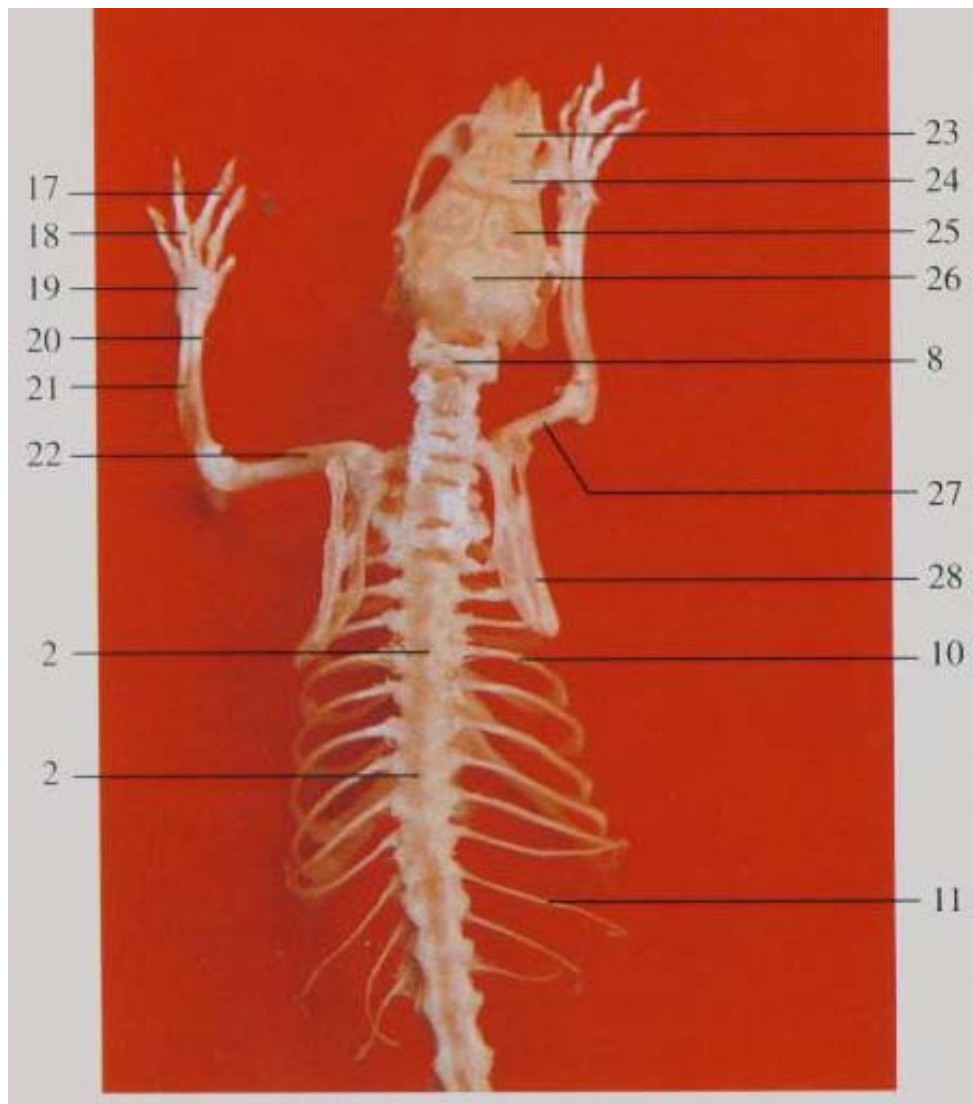

- |                        |                          |
|------------------------|--------------------------|
| 1 背肋 dorsal rib        | 2 胸椎 thoracic vertebra   |
| 3 颈椎 cervical vertebra | 4 顶间骨 interparietal bone |
| 5 顶骨 parietal bone     | 6 额骨 frontal bone        |
| 7 鼻骨 nasal bone        | 8 锁骨 clavicle            |
| 9 肩胛骨 scapula          | 10 肱骨 humerus            |
| 11 髌骨 patella          | 12 腰椎 lumbar vertebra    |
| 13 荐椎 sacral vertebra  | 14 尾椎 caudal vertebra    |
| 15 坐骨 ischium          | 16 髌骨 ilium              |
| 17 股骨 femur            | 18 腓骨 fibula             |
| 19 胫骨 tibia            | 20 跖骨 metatarsal bone    |
| 21 趾骨 digital bone     | 22 胸肋 sternal rib        |
| 23 头骨 skull            | 24 指骨 digital bone       |
| 25 桡骨 radius           |                          |

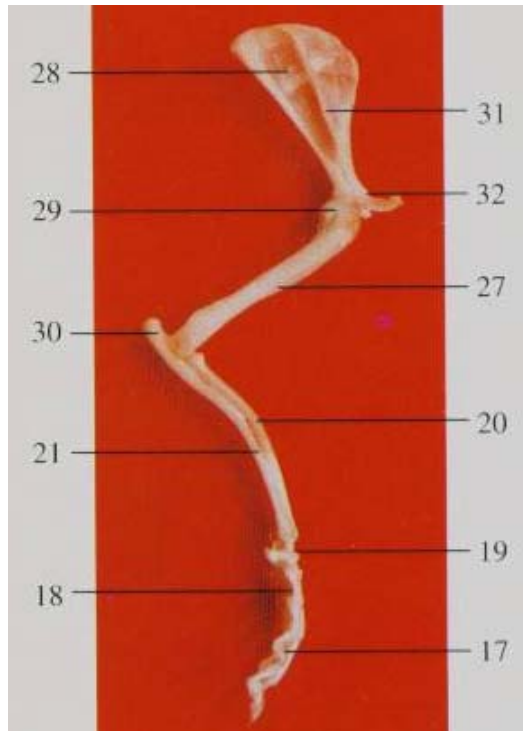
图IX-3 脊柱背面 The vertebral column. Dorsal aspect



图IX-4 胸廓背面 The thorax. Dorsal aspect

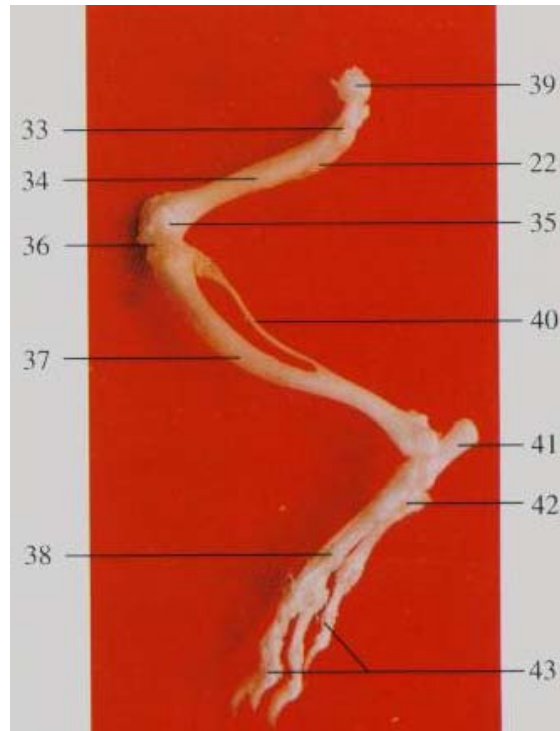


图IX -5 前肢骨内侧面 The bone of anterior limb.Medial aspect



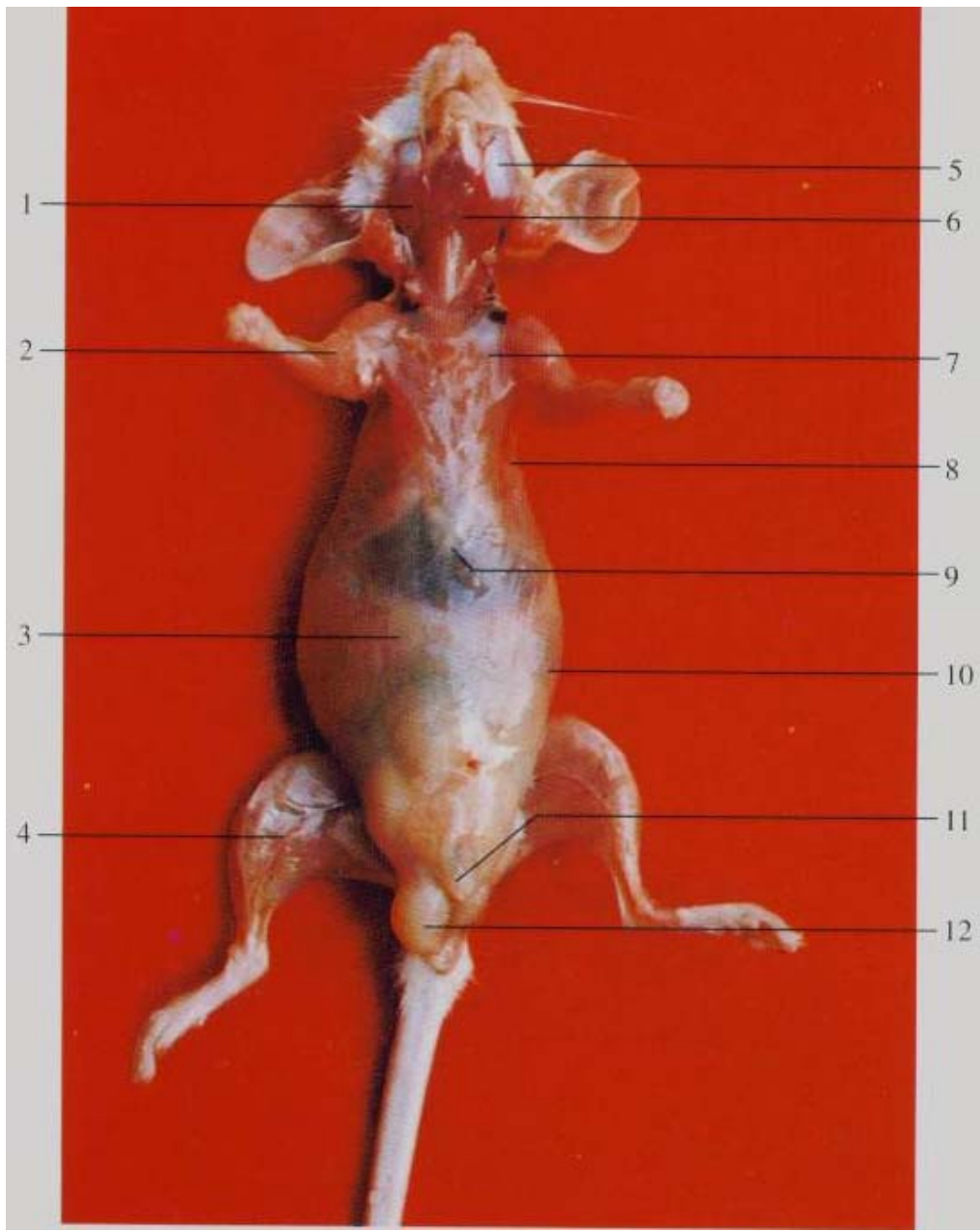- 1 枢椎 axis
- 3 第 II 胸椎 I Ith thoraac vertebra
- 5 第 6 腰椎 6th lumbar vertebra
- 7 闭孔 obturator foramen
- 9 第 7 颈椎 seventh cervical vertebra
- 11 背肋 dorsal rib
- 13 髌骨 ilium
- 15 坐骨 ischimm
- 17 指骨 digital bone
- 19 腕骨 carpal bone
- 21 尺骨 ulna
- 23 鼻骨 nasal bone
- 25 顶骨 parietal bone
- 27 肱骨 hemerus
- 29 肱骨头 head of humerus
- 31 肩胛冈 spine of scapula

图IX-6 后肢骨外侧面 The bone of posterior limb.Lateral aspect

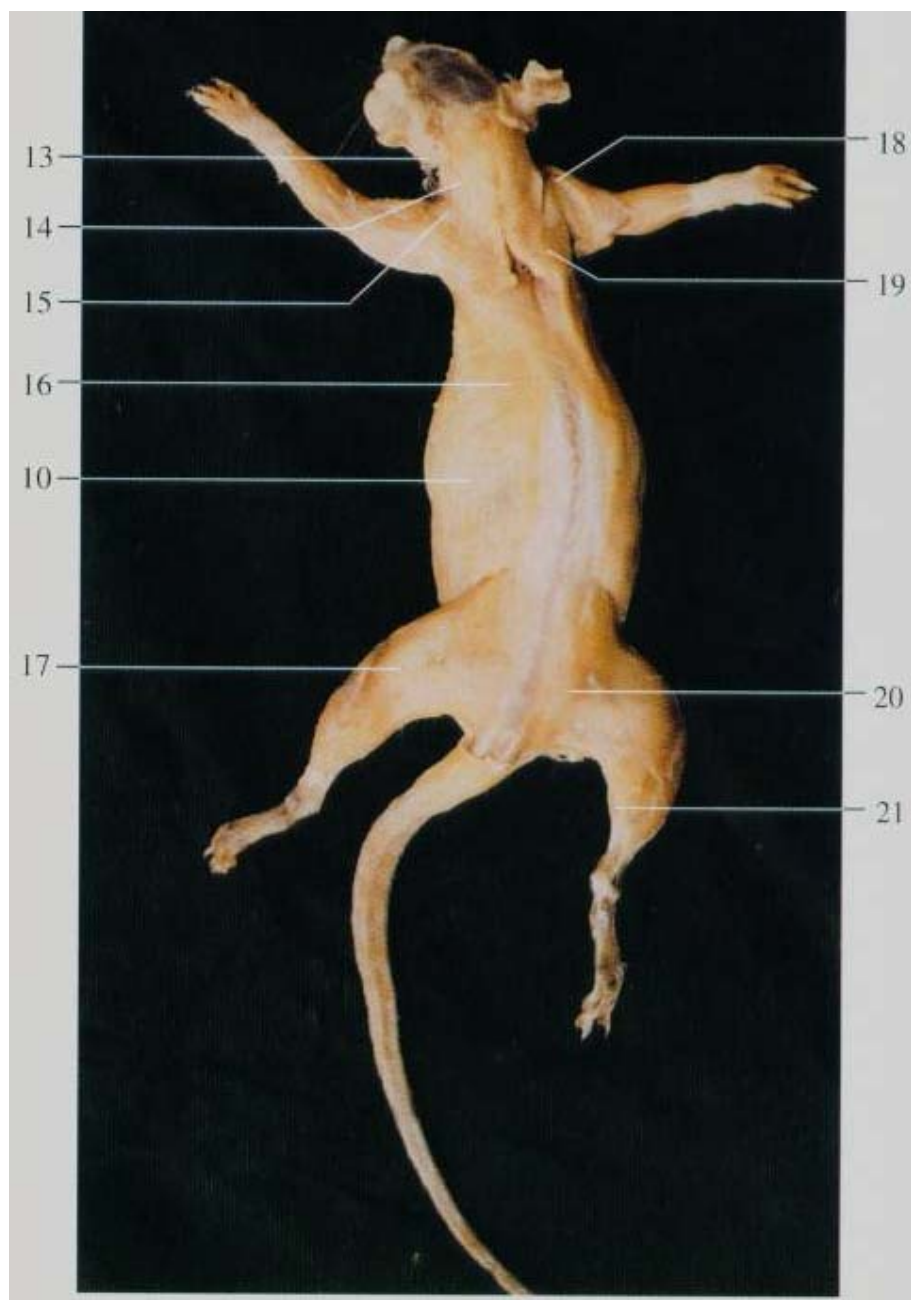


- 2 胸椎 thoracic vertebra
- 4 第 1 腰椎 I st lumbar vertebra
- 6 耻骨 pubis
- 8 寰椎 atlas
- 10 胸肋 sternal rib
- 12 第 4 腰椎 4th lumbar
- 14 荐椎 sacral vertebra
- 16 尾椎 caudal vertebra
- 18 掌骨 metacarp at bone
- 20 桡骨 radius
- 22 三角突起 deltoid process
- 24 额骨 frontal bone
- 26 项间骨 interparietal bone
- 28 肩胛骨 scapula
- 30 肘突 elbow process
- 32 肩带 pectoral girdle
- 34 股骨 femur
- 36 髌骨 patella
- 38 跖骨 metatarsal bone
- 40 腓骨 fibula
- 42 跗骨 tarsal bone

图IX-7 整体肌腹面观 The muscles. Ventral view

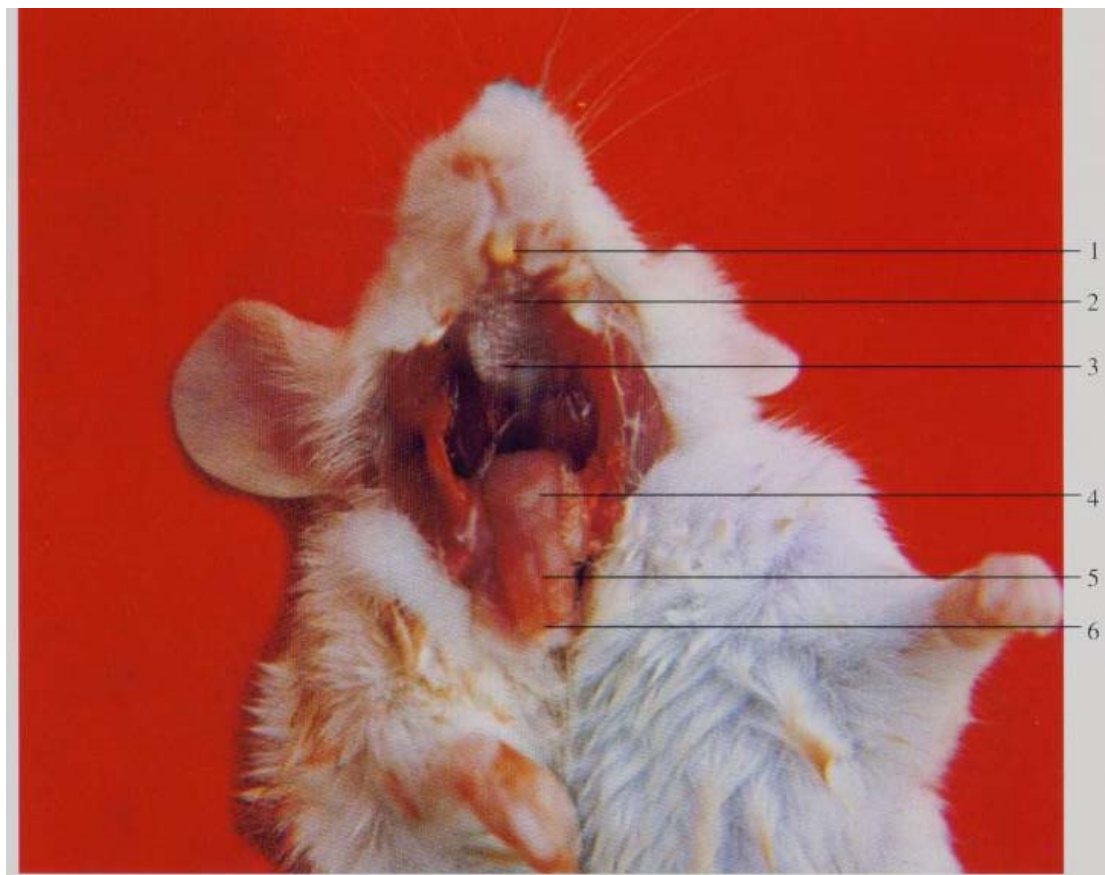

图IX-8 整体肌背面观 The muscles. Dorsal view

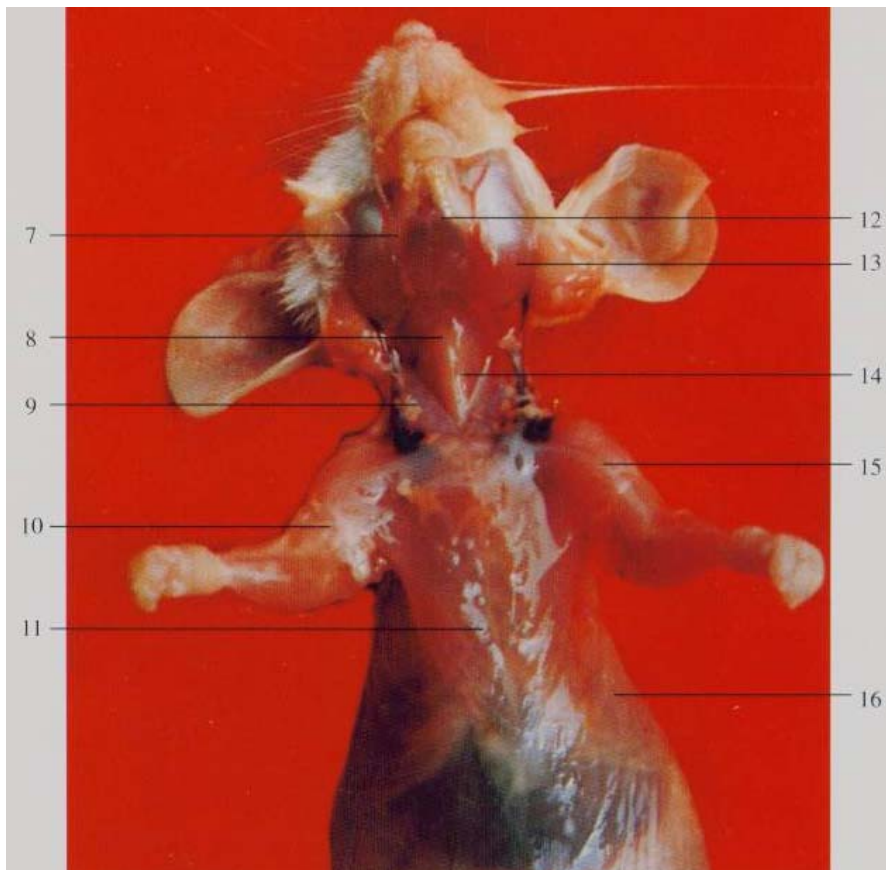


- |  |  |
|--|--|
| 1 二腹肌前腹 anterior belly of digastric muscle | 2 肱二头肌 biceps brachii muscle               |
| 3 腹直肌 rectus abdominis muscle              | 4 股动脉 femoral artery                       |
| 5 咬肌 masseter muscle                       | 6 颌下腺 submandibular gland                  |
| 7 胸浅肌 pectoral superficialis muscle        | 8 前锯肌 serratus anterior muscle             |
| 9 剑突 xiphoid process                       | 10 腹外斜肌 external oblique muscle of abdomen |
| 11 阴茎 penis                                | 12 阴囊 scrotum                              |
| 13 耳提肌 levator auricularis muscle          | 14 颈阔肌 platysma                            |
| 15 肩三角肌 shoulder-deltoid muscle            | 16 背阔肌 latissimus dorsi muscle             |
| 17 股直肌 rectus femoris muscle               | 18 锁骨提肌 levator claudalis muscle           |
| 19 背斜方肌 trapezius dorsi muscle             | 20 臀浅肌 gluteus superficialis muscle        |
| 21 半腱肌 semitendinosus muscle               |  |

图IX-9 口腔 The oral cavity



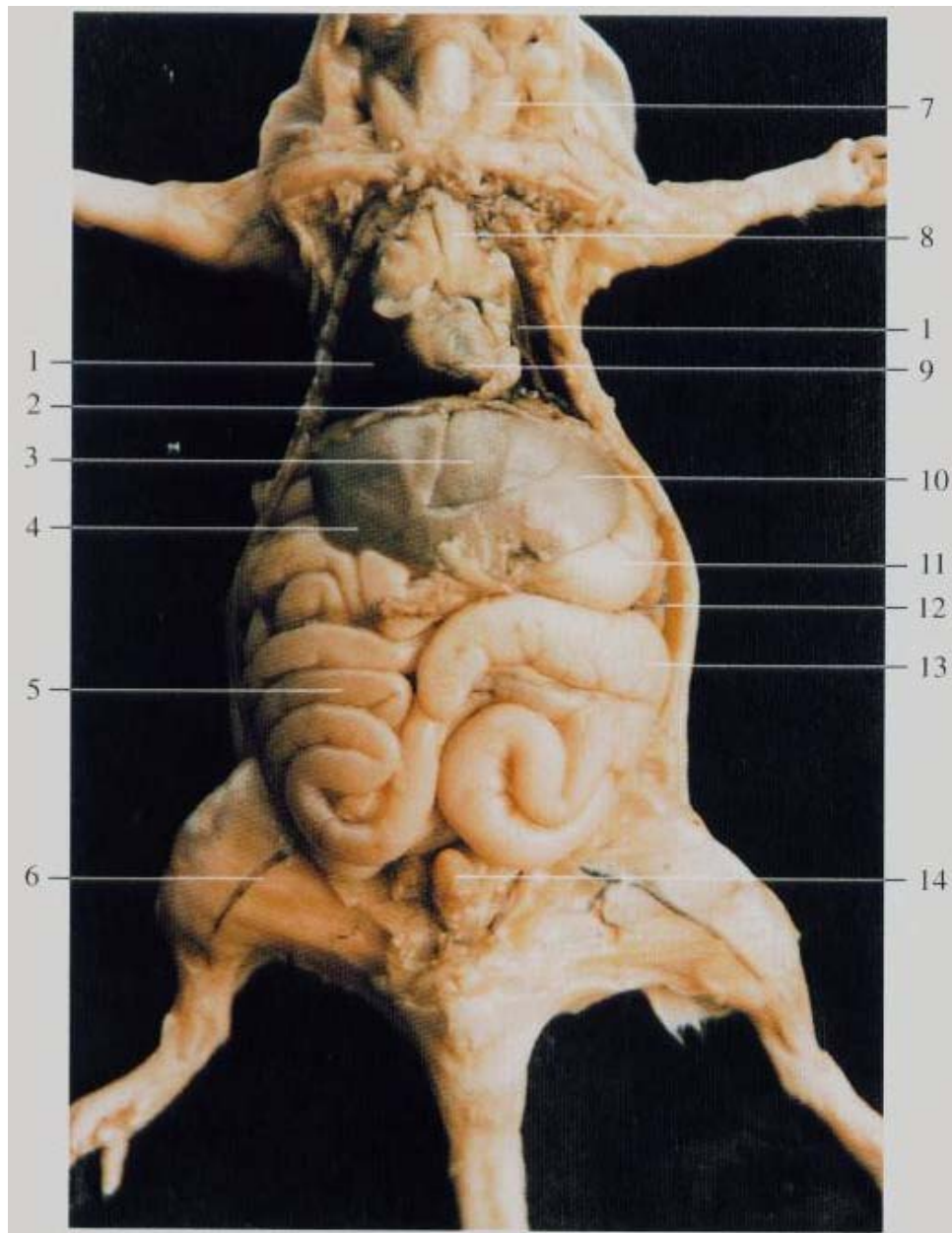
图IX-10 颈肌与胸肌 The muscle of neck and pectoral muscle



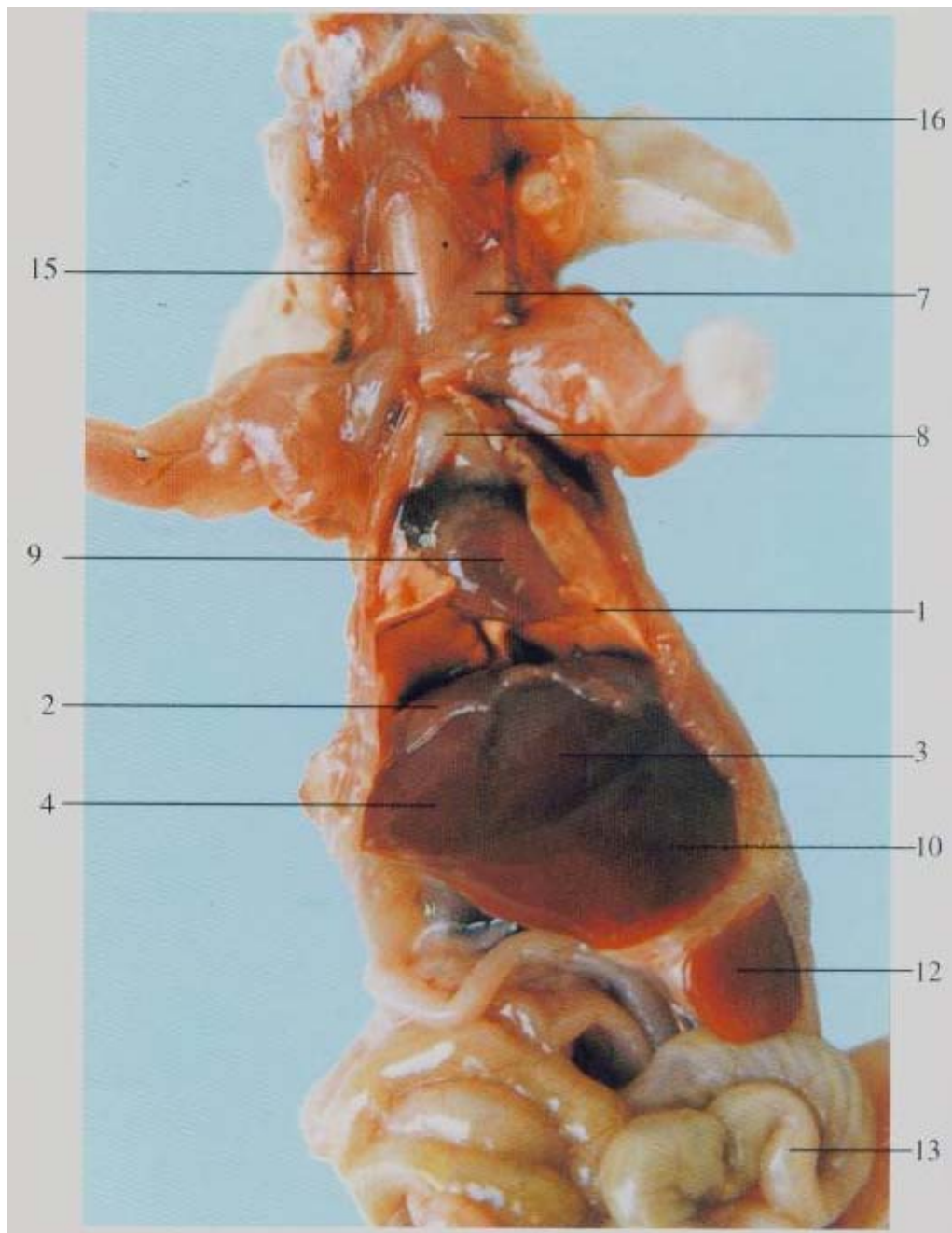- 1 门齿 incisor tooth
- 2 硬腭 hard palate
- 3 软腭 soft palate
- 4 舌根 root of tongue
- 5 舌体 body of tongue
- 6 舌尖 apex of tongue
- 7 颞浅动脉 superficial temporal artery
- 8 二腹肌后腹 posterior belly of digastric muscle
- 9 胸乳突肌 sternomastoideus muscle
- 10 肱二头肌 biceps brachii muscle
- 11 胸浅肌 pectoral superficialis muscle
- 12 二腹肌前腹 anterior belly of digastric muscle
- 13 咬肌 masseter muscle
- 14 胸骨舌骨肌 stemohyoid muscle
- 15 肩三角肌 shoulder-deltoid muscle
- 16 前锯肌 serratus anterior muscle



图IX-11 胸、腹腔器官(1)The organs in the thoracic and abdominal cavities (1)



图IX-12 胸、腹腔器官 (2) The organs in the thoracic and abdominal cavities (2)



1 肺 lung

3 肝中叶 middle lobe of liver

5 小肠 small intestine

7 胸乳突肌 sternomastoideus muscle

9 心 heart

11 胃 stomach

13 结肠 colon

15 气管 trachea

2 膈 diaphragm

4 肝右叶 right lobe of liver

6 股动、静脉 femoral artery and vein

8 胸腺 thymus

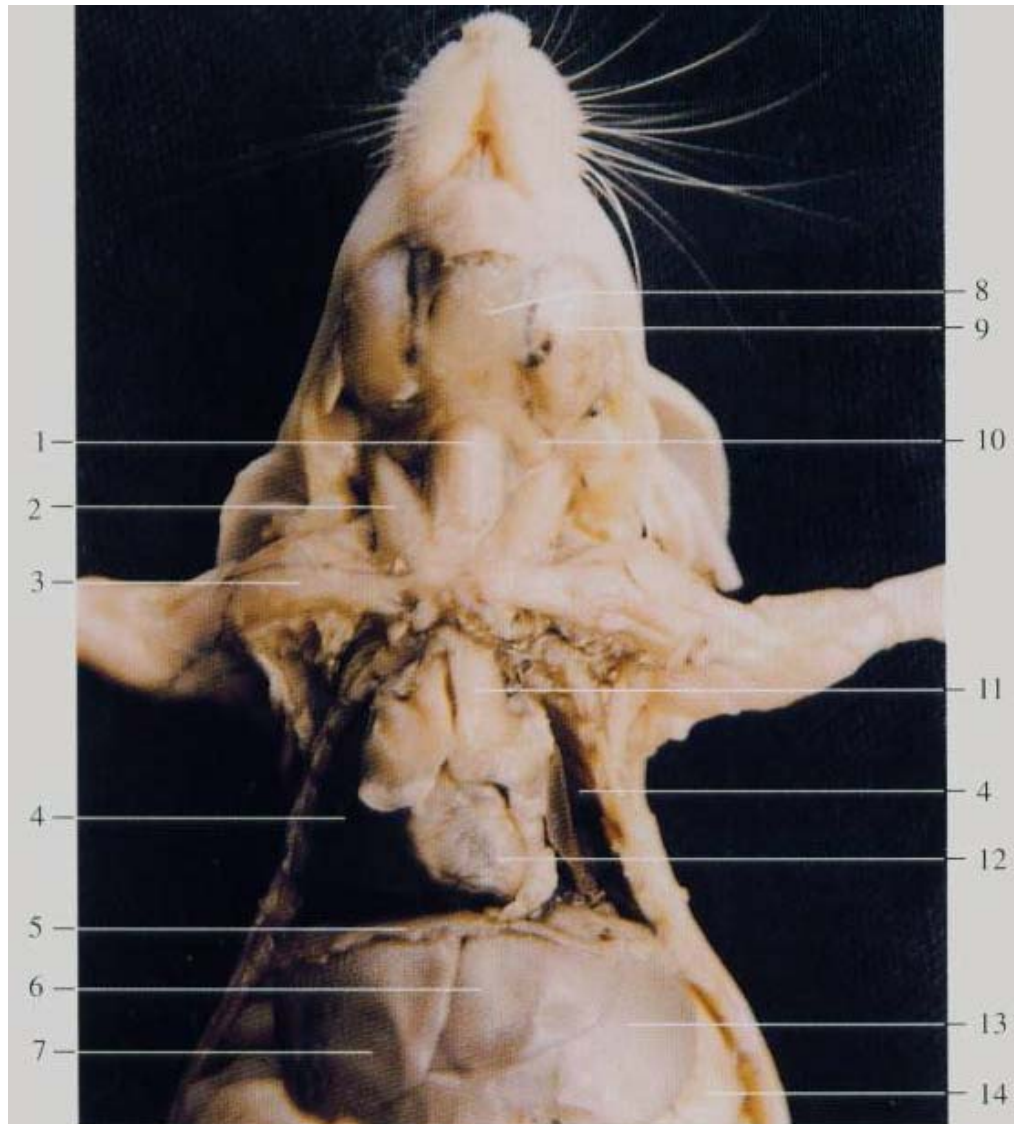
10 肝左叶 left lobe of liver

12 脾 spleen

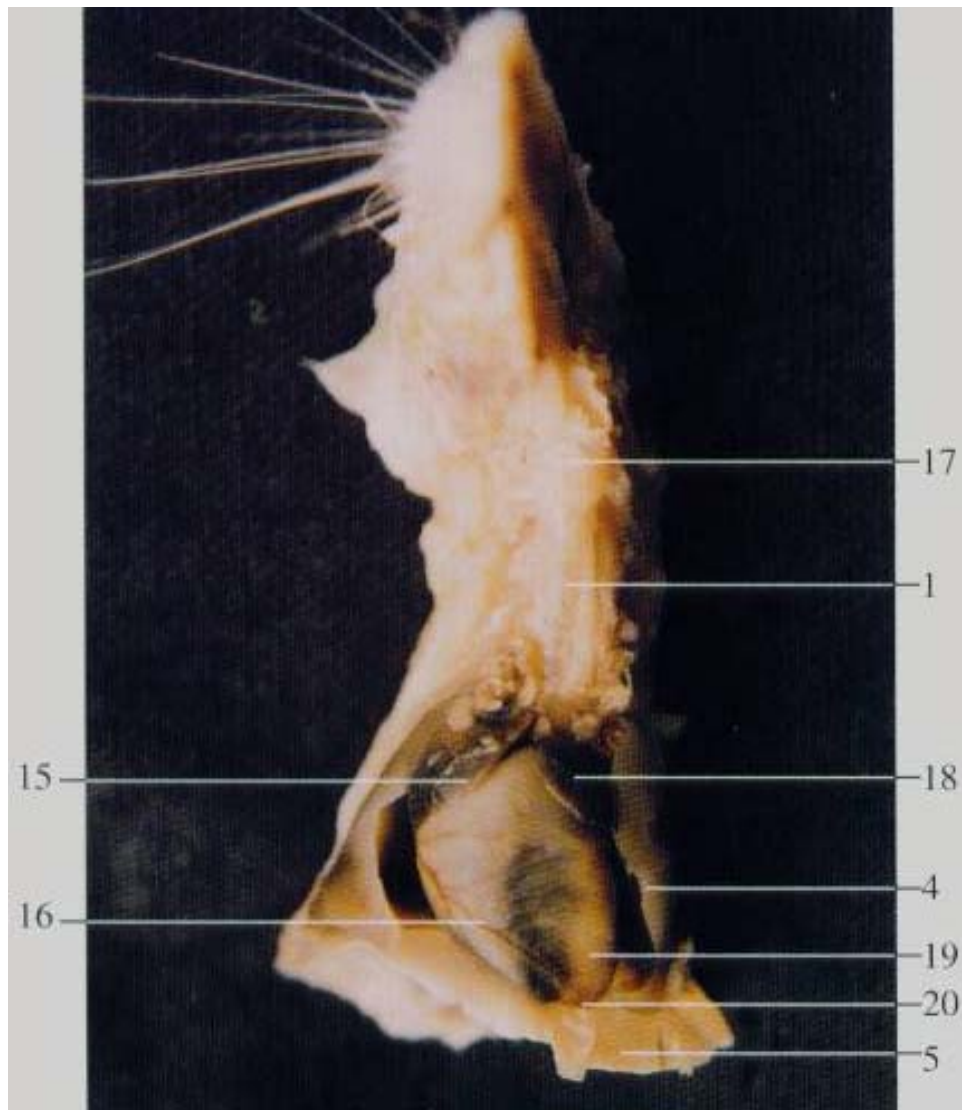
14 膀胱 urinary bladder

16 咬肌 masseter muscle

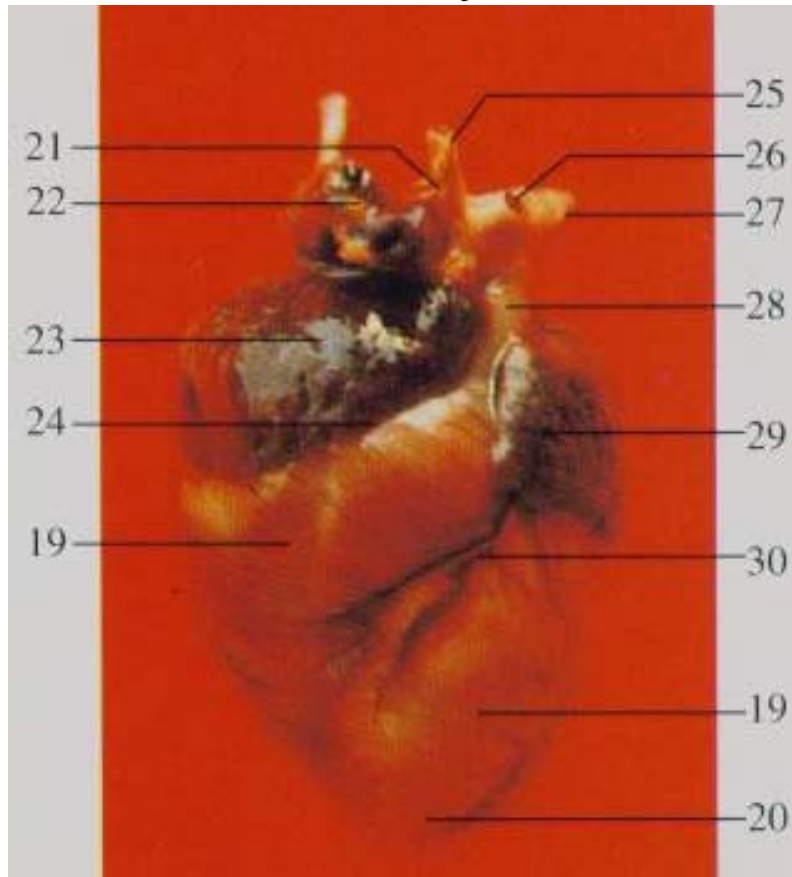
图IX-13 胸腔器官 The organs in the thoracic cavity



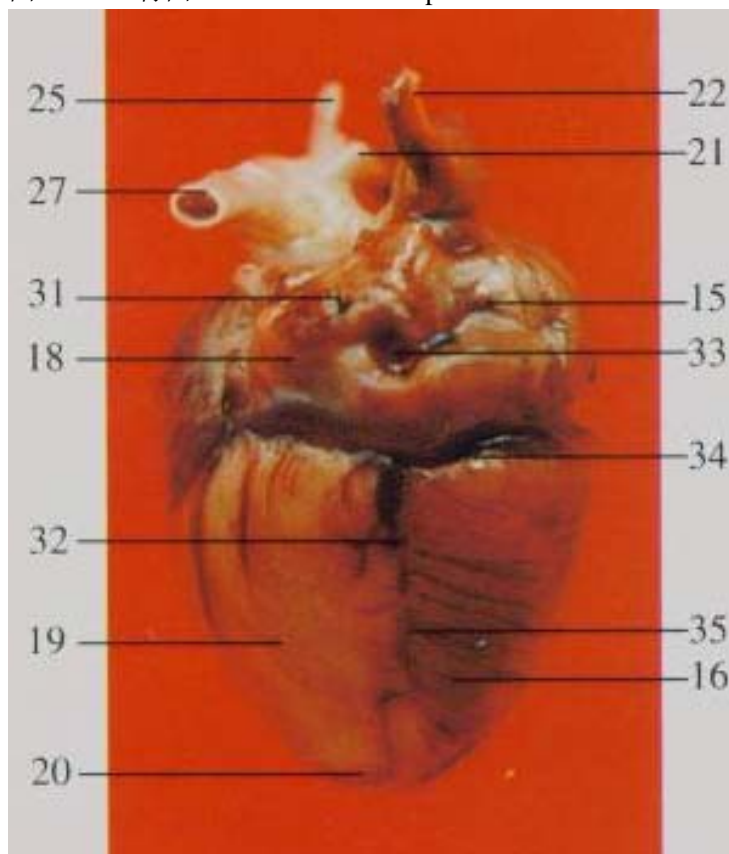
图IX-14 心腹面(1)The heart. Ventral aspect (1)



图IX-15 心腹面(2)The heart. Ventral aspect (2)

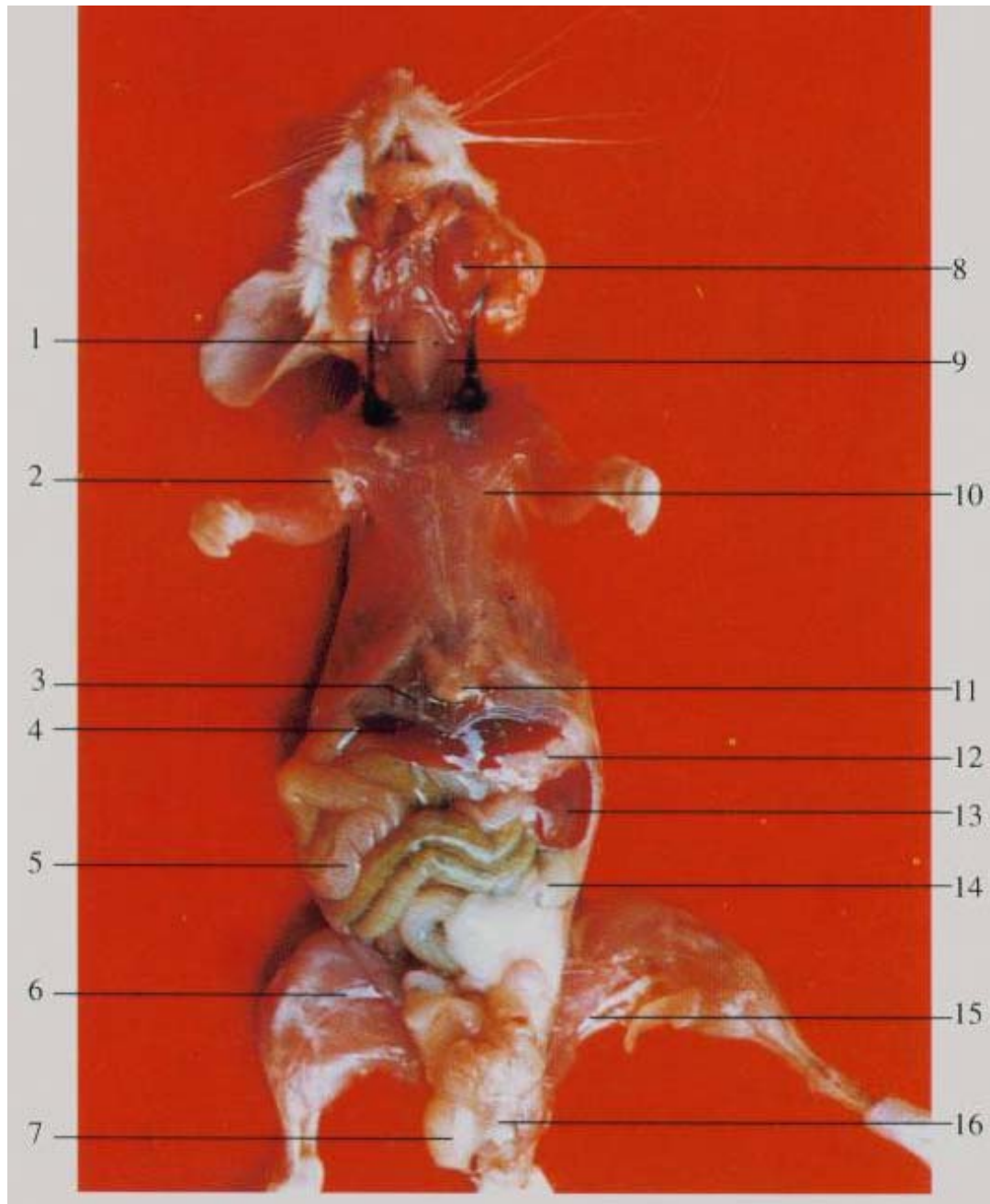

图IX-16 心背面 The heart. Dorsal aspect

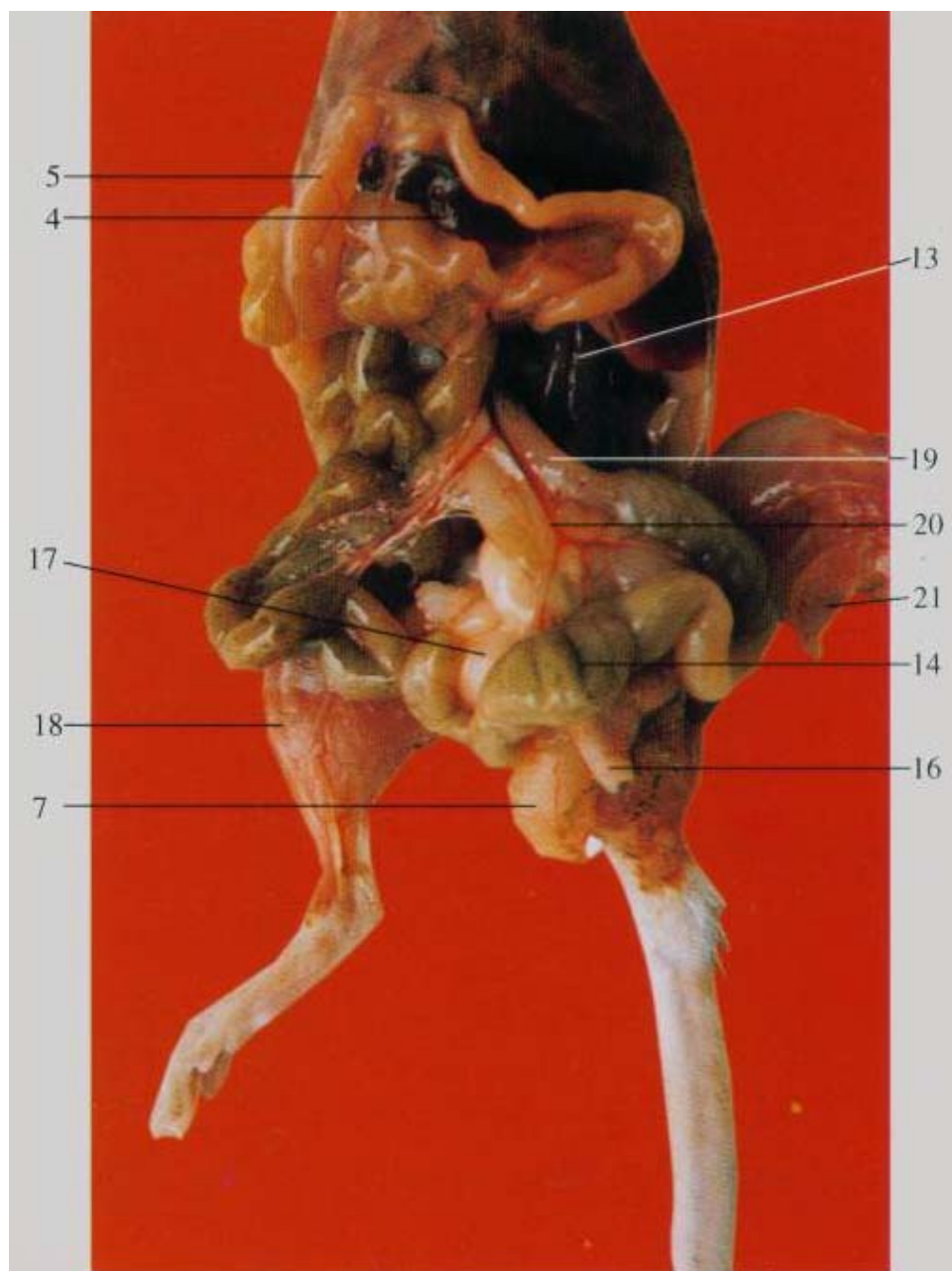


- 1 气管 trachea
- 2 胸乳突肌 sternomastoideus muscle
- 3 肱二头肌 biceps brachii muscle
- 4 肺 lung
- 5 膈 diaphragm
- 6 肝中叶 middle lobe of liver
- 7 肝右叶 right lobe of liver
- 8 二腹肌前腹 anterior belly of digastric muscle
- 9 咬肌 masseter muscle
- 10 二腹肌后腹 posterior belly of digastric muscle
- 11 胸腺 thymus
- 12 心 heart
- 13 肝左叶 left lobe of liver
- 14 胃 stomach
- 15 右心房 right atrium
- 16 右心室 right ventricle
- 17 喉 larynx
- 18 左心房 left atrium
- 19 左心室 left ventricle
- 20 心尖 cardiac apex
- 21 右锁骨下动脉 right subclavian artery
- 22 前腔静脉 precaval vein
- 23 右心耳 right auricle
- 24 冠状沟 coronary sulcus
- 25 颈总动脉 common carotid artery
- 26 左锁骨下动脉 left subclavian artery
- 27 主动脉 aorta
- 28 肺动脉 pulmonary artery
- 29 左心耳 left auricle
- 30 左冠状动脉 left coronary artery
- 31 肺静脉 pulmonary vein
- 32 心中静脉 middle cardiac vein
- 33 后腔静脉 postcaval vein
- 34 冠状窦 coronary sinus
- 35 背面室间沟 dorsal interventricular groove

图IX-17 腹腔器官 (1)The organs in the abdominal cavity (1)



图IX-18 腹腔器官 (2)The organs in the abdominal cavity (2)



- |                               |                                       |
|-------------------------------|---------------------------------------|
| 1 胸骨舌骨肌 stemohyoid muscle     | 2 肱二头肌 biceps brachii muscle          |
| 3 膈 diaphragm                 | 4 肝 liver                             |
| 5 空肠 jejunum                  | 6 股动、静脉 femoral artery and vein       |
| 7 阴囊 scrotum                  | 8 咬肌 masseter muscle                  |
| 9 胸乳突肌 stemomastoideus muscle | 10 胸浅肌 pectoral superficialis muscle  |
| 11 剑突 xiphoid process         | 12 胃 stomach                          |
| 13 脾 spleen                   | 14 结肠 colon                           |
| 15 坐骨神经 sciatic nerve         | 16 阴茎 penis                           |
| 17 膀胱 urinary bladder         | 18 股直肌 rectus femoris muscle          |
| 19 回肠 ileum                   | 20 后肠系膜动脉 posterior mesenteric artery |
| 21 股薄肌 gracilis muscle        |                                       |



图 IX-19 腹腔器官 (3) The organs in the abdominal cavity (3)

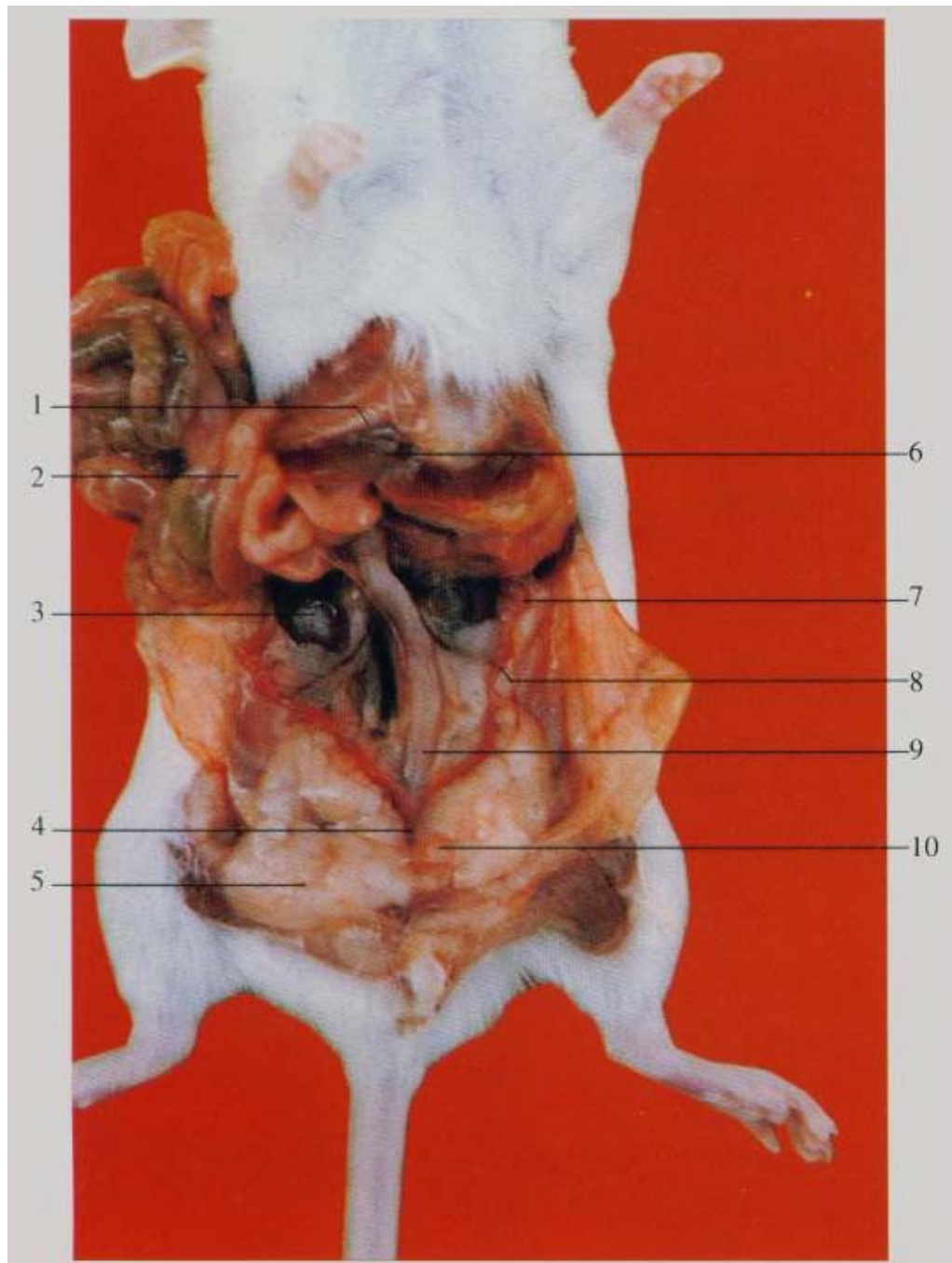
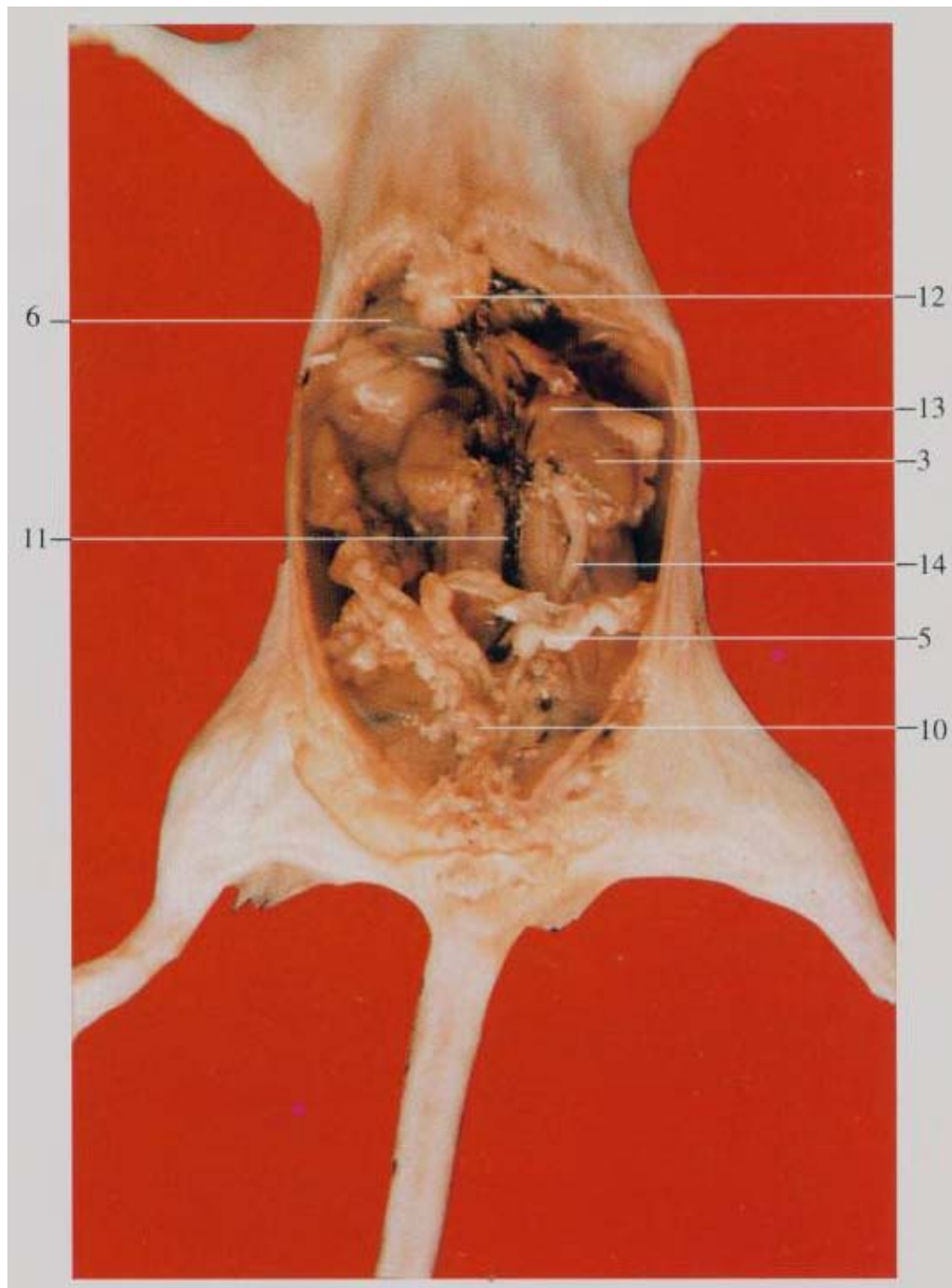
图 IX -20 腹腔器官 (4) The organs in the abdominal cavity (4)



1 肋弓 costal arch

3 肾 kidney

5 脂肪 fat

7 卵巢 ovary

9 直肠 rectum

11 后腔静脉 postcaval vein

13 肾上腺 adrenal gland

2 小肠 small intestine

4 阴道 vagina

6 肝 liver

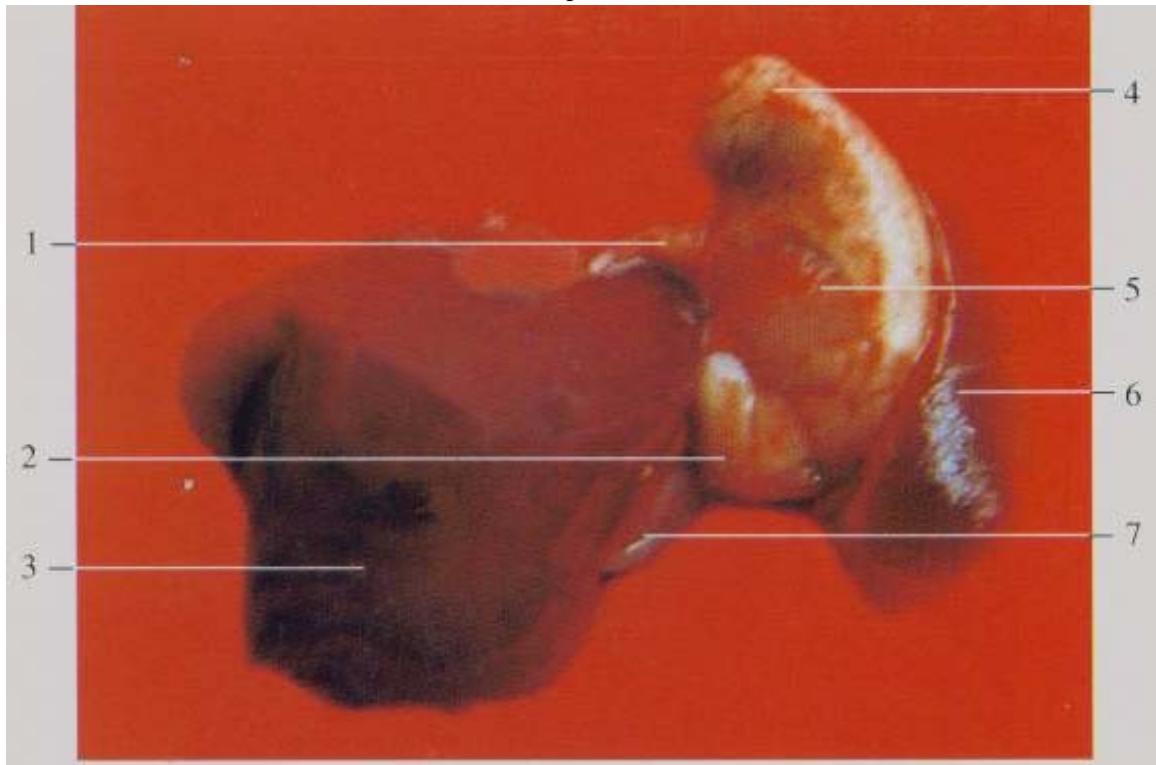
8 子宫 uterus

10 膀胱 urinary bladder

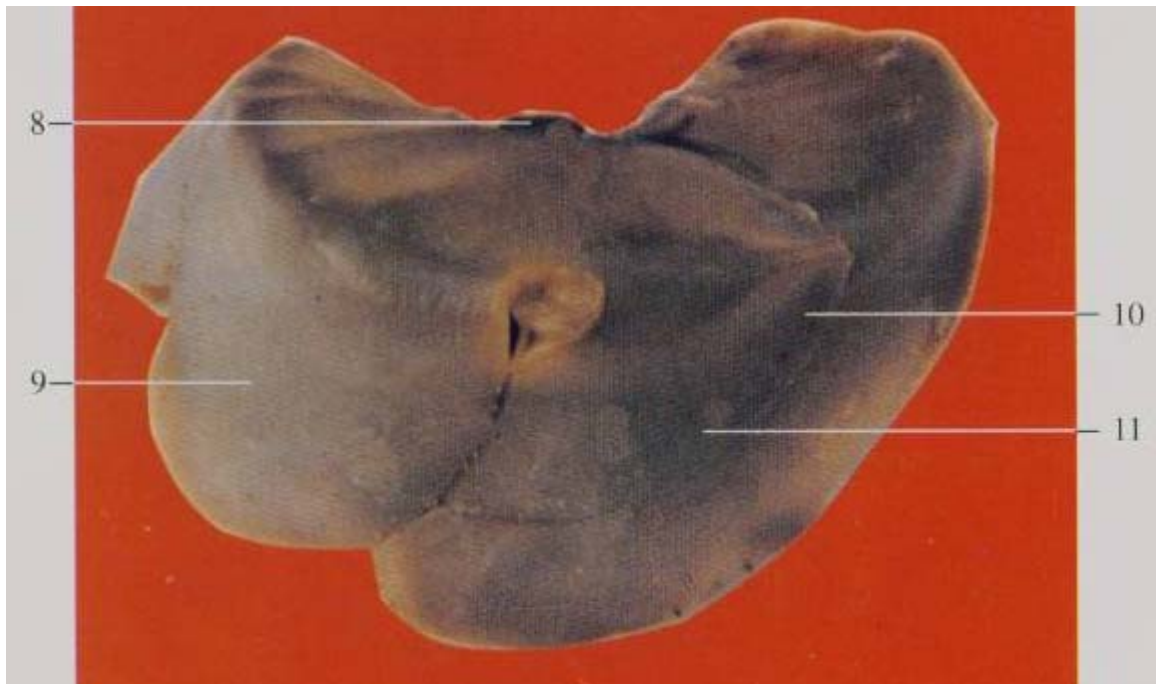
12 剑突 xiphoid process

14 输尿管 ureter

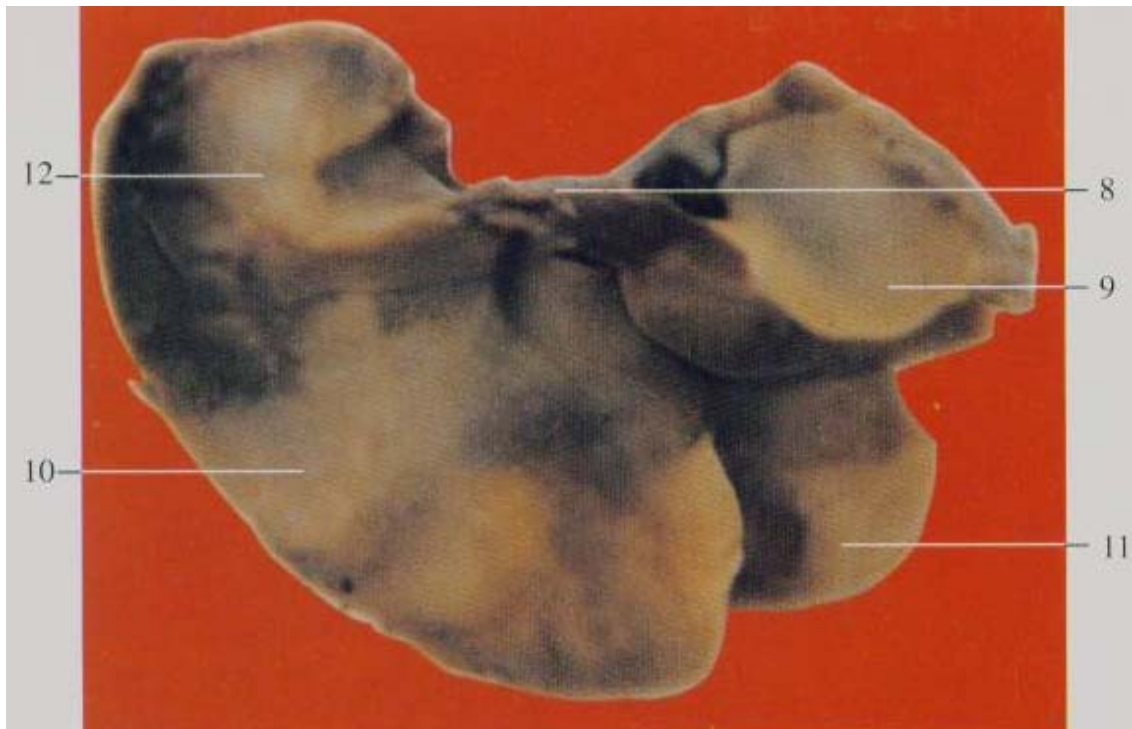
图IX-21 肝、胃与脾 The liver, stomach and spleen



图IX-22 肝腹面 The liver. Ventral aspect

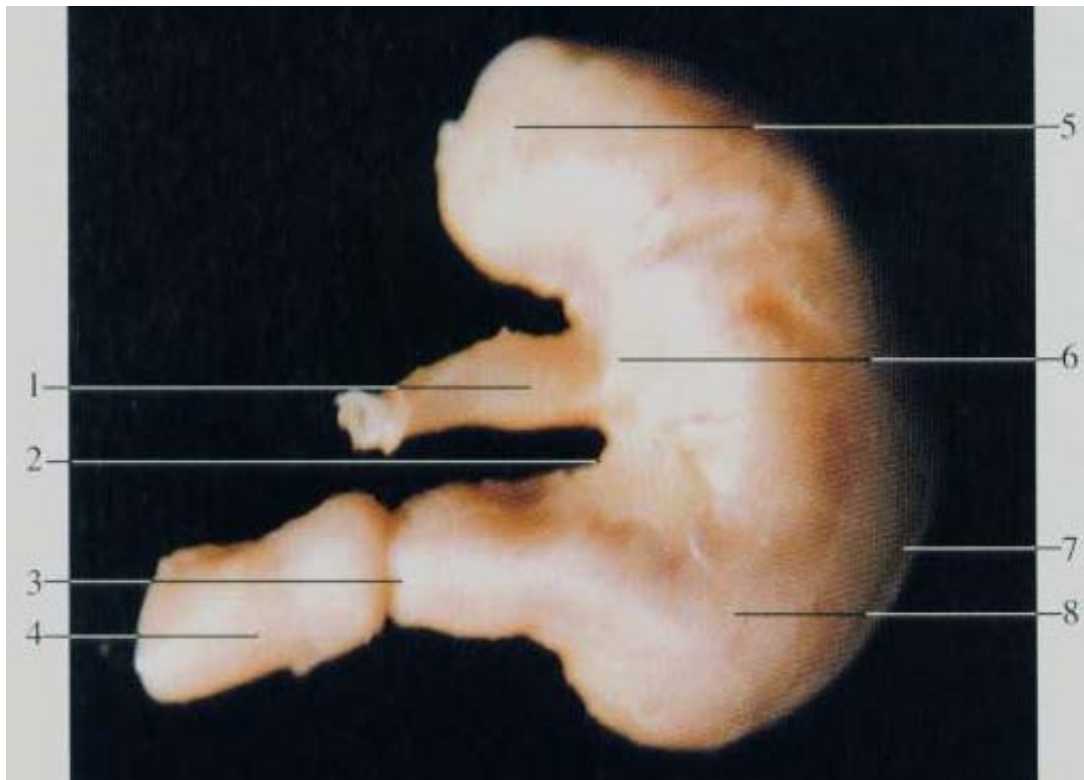


图IX-23 肝背面 The liver. Dorsal aspect

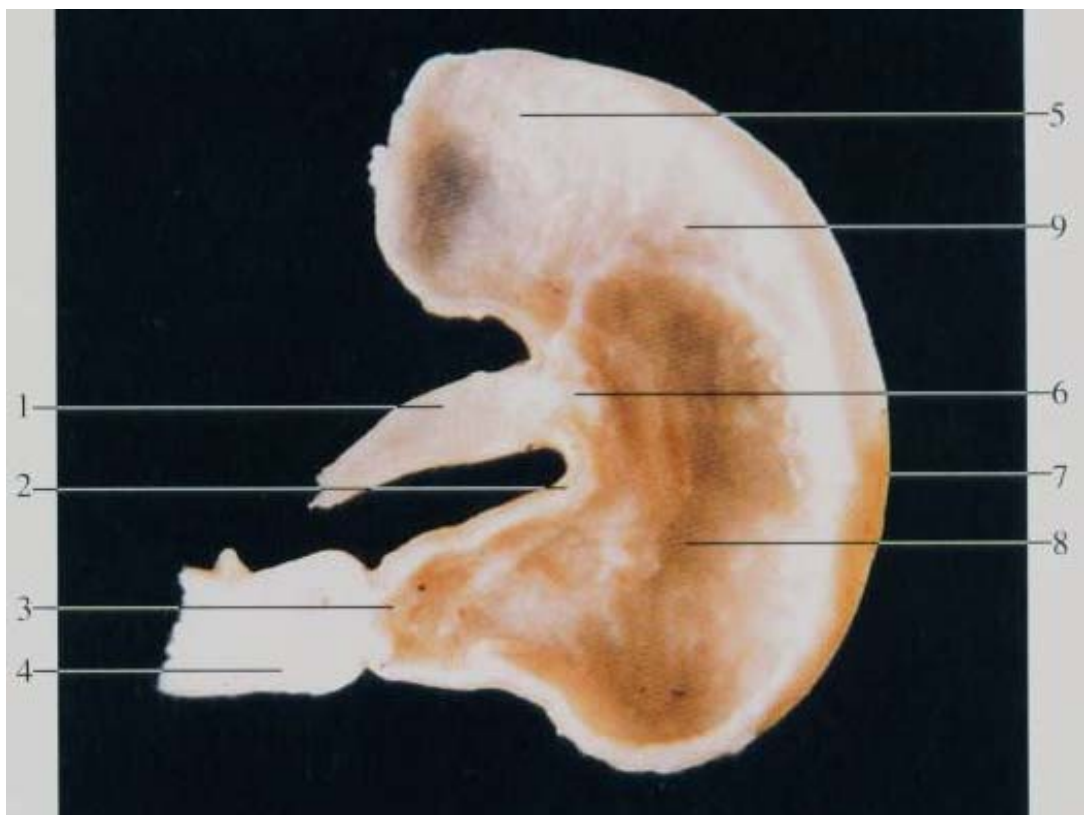


- 1 食管 esophagus
- 2 幽门 pylorus
- 3 肝 liver
- 4 胃底 fundus of stomach
- 5 胃体 body of stomach
- 6 脾 spleen
- 7 胰 pancreas
- 8 前腔静脉 precaval vein
- 9 肝右叶 right lobe of liver
- 10 肝左叶 left lobe of liver
- 11 肝中叶 middle lobe of liver
- 12 肝尾叶 caudate lobe of liver

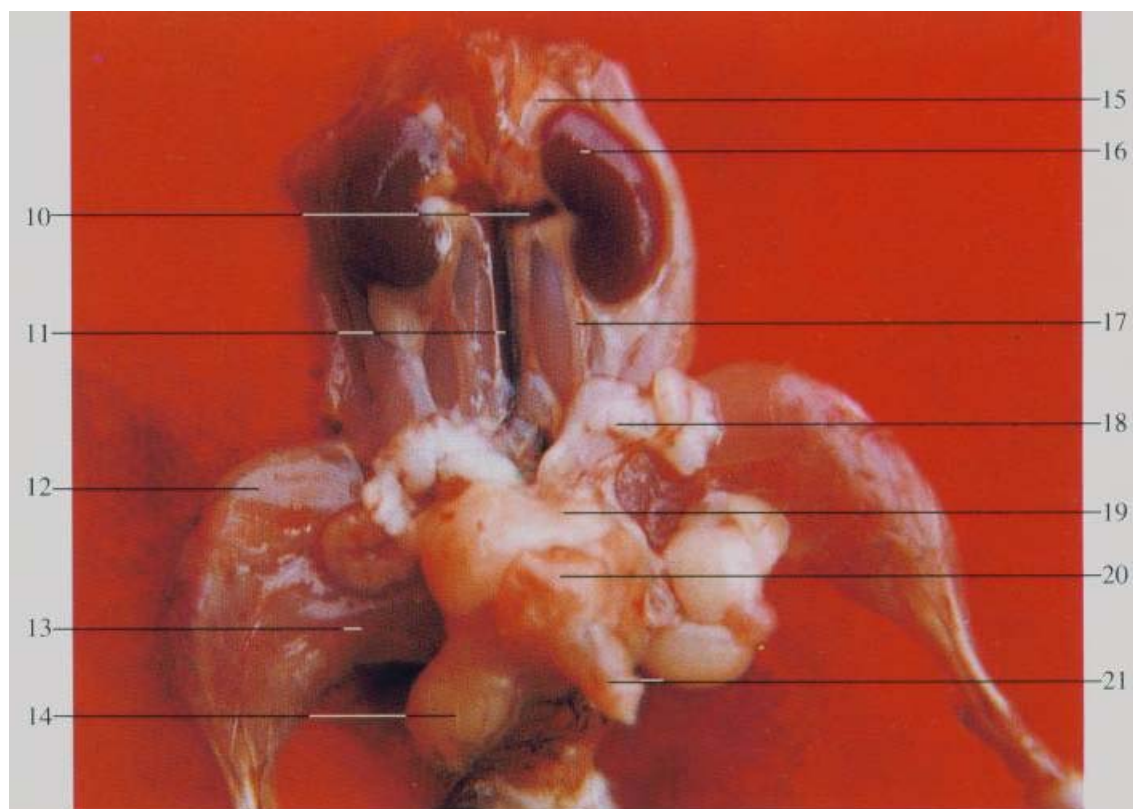
图IX-24 胃 The stomach



图IX-25 胃壁内面 The wall of stomach. Inner surface

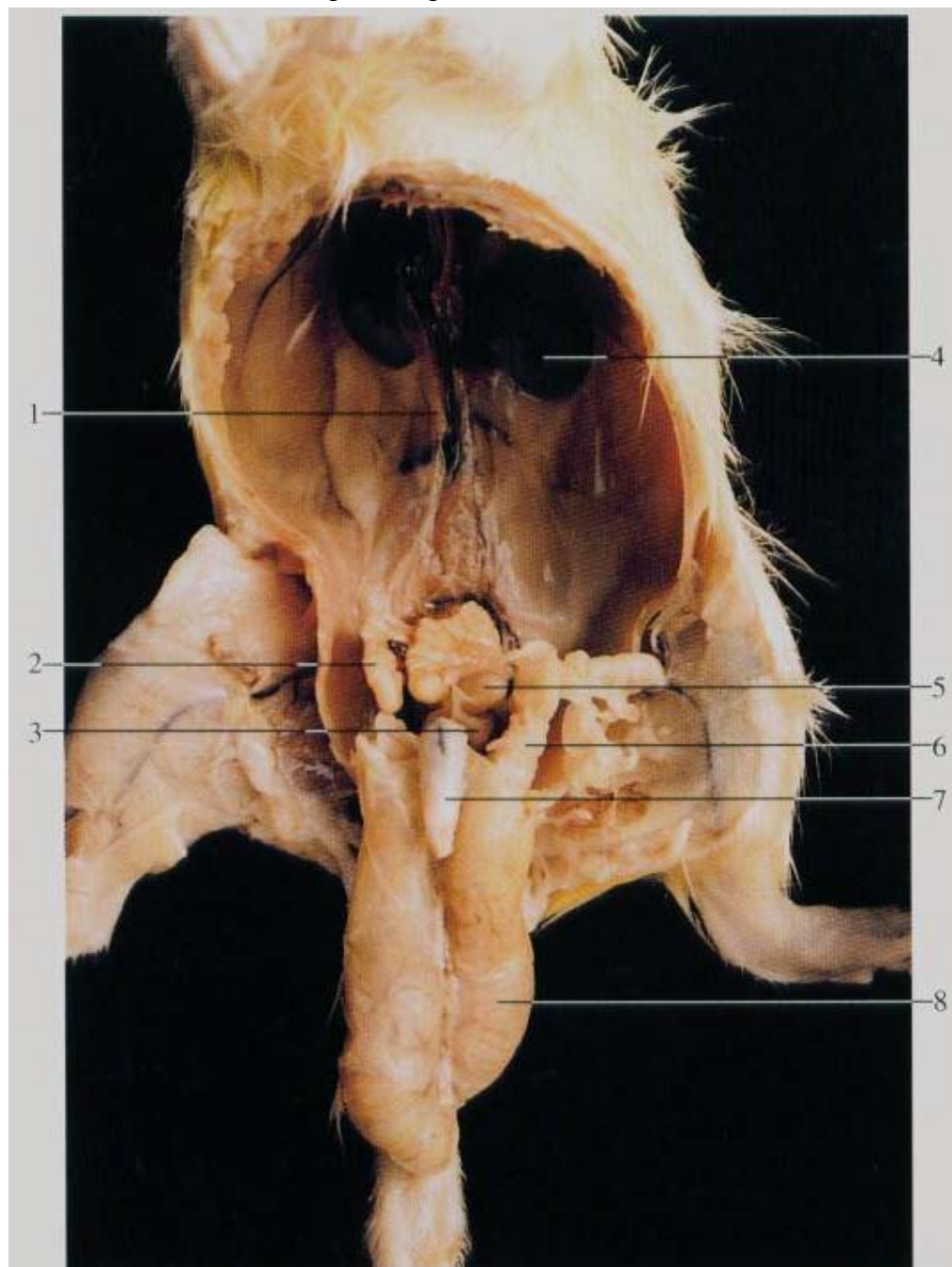


图IX-26 泌尿、生殖器官 (♂) The urinary and genital organs (♂)

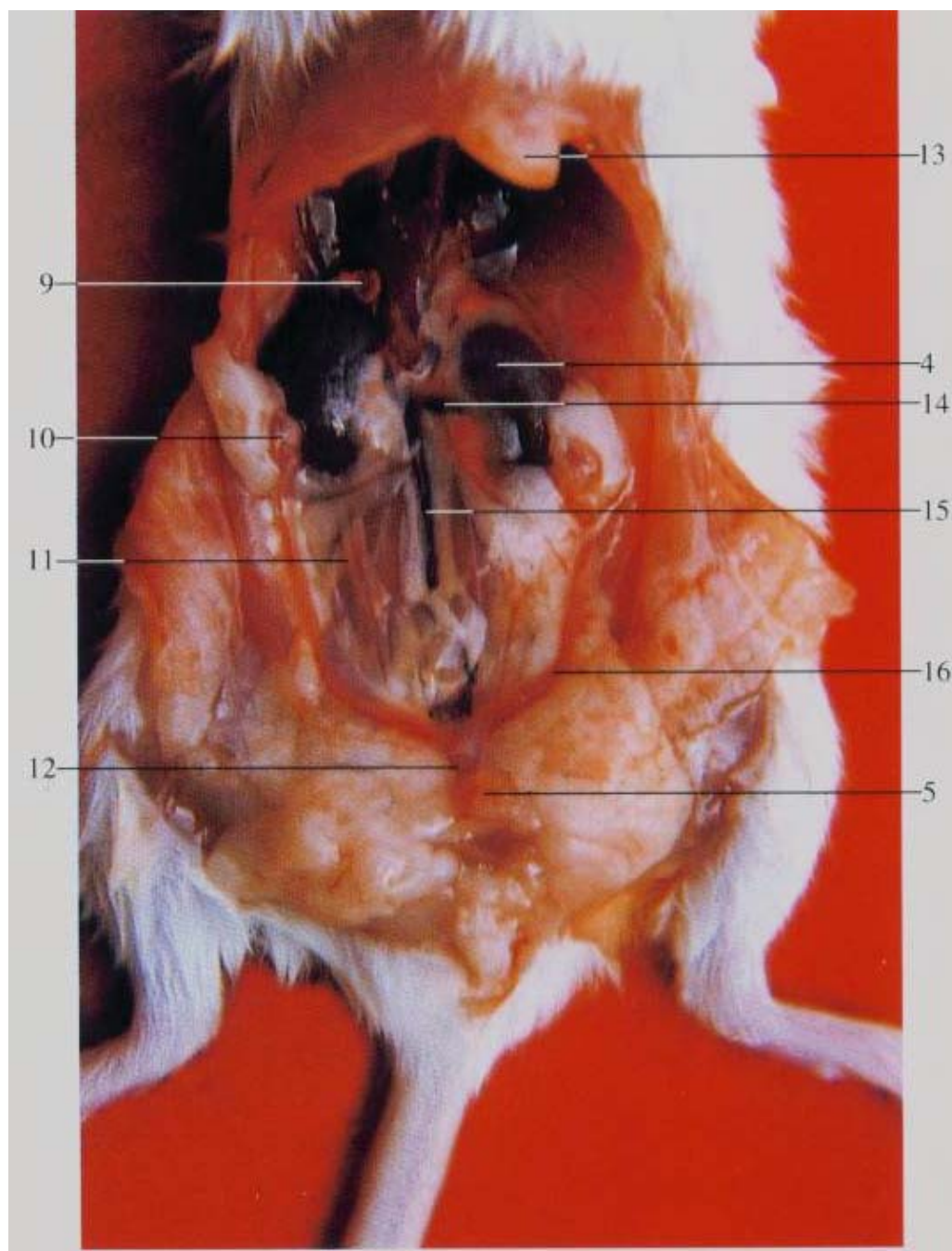


- 1 食管 esophagus
- 2 胃小弯 lesser curvature of stomach
- 3 幽门 pylorus
- 4 十二指肠 duodenum
- 5 胃底 fundus of stomach
- 6 贲门 cardia
- 7 胃大弯 greater curvature of stomach
- 8 胃体 body of stomach
- 9 皮区 cutaneous region
- 10 肾静脉 renal vein
- 11 后腔静脉 postcaval vein
- 12 股直肌 rectus femoris muscle
- 13 内收肌 adductor medial muscle
- 14 阴囊 scrotum
- 15 肾上腺 adrenal gland
- 16 肾 kidney
- 17 输尿管 ureter
- 18 精囊 seminal vesicle
- 19 脂肪 fat
- 20 膀胱 urinary bladder
- 21 阴茎 penis

图IX-27 生殖器官 (♂) The genital organs (♂)



图IX-28 泌尿、生殖器官（♀） The urinary and genital organs（♀）

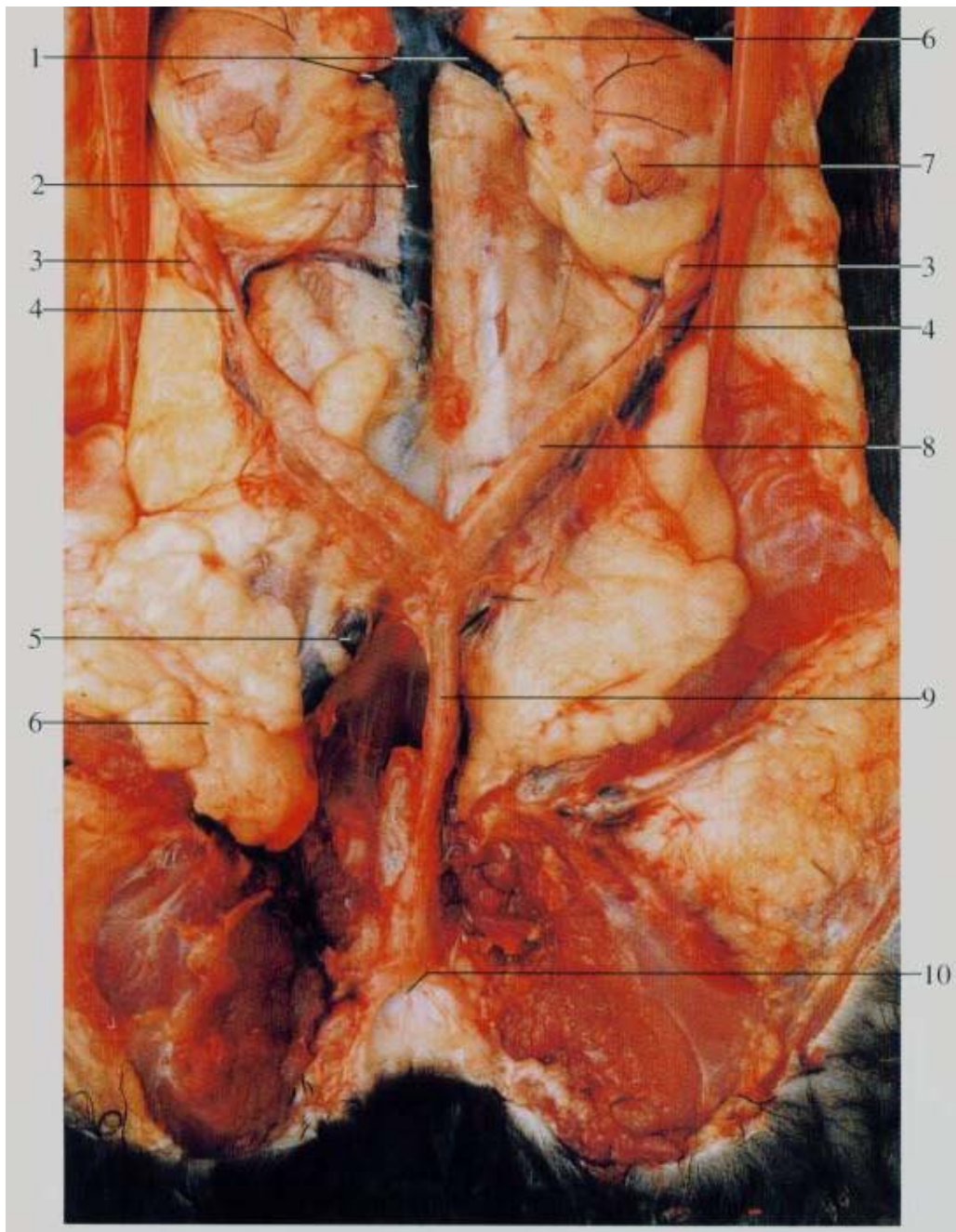

- 1 输尿管 ureter
- 3 前列腺 prostate
- 5 膀胱 urinary bladder
- 7 阴茎 penis
- 9 肾上腺 adrenal gland
- 11 输卵管 uterine tube
- 13 剑突 xiphoid process
- 15 后腔静脉 postcaval vein

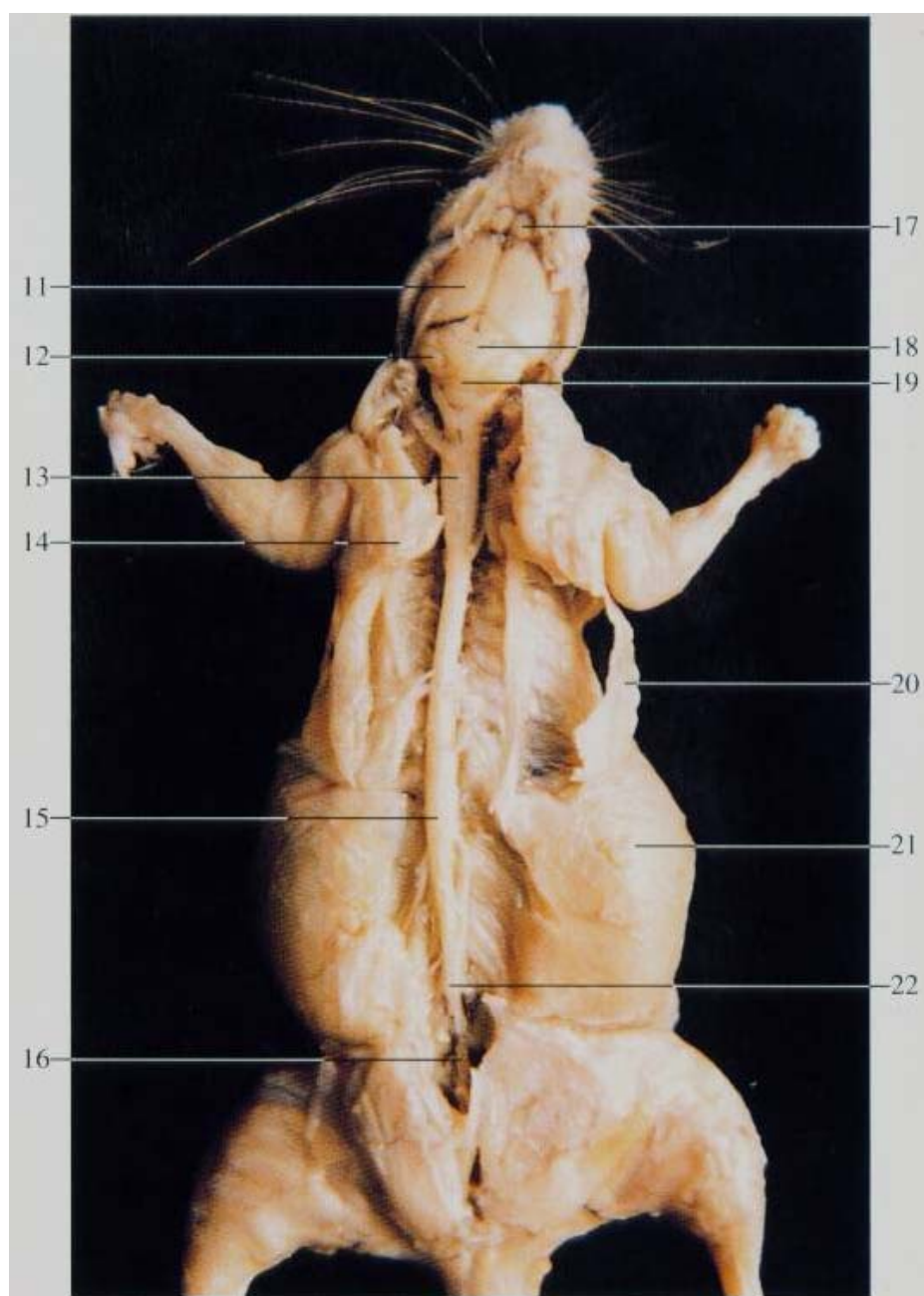
- 2 精囊 seminal vesicle
- 4 肾 kidney
- 6 精索 spermatic cord
- 8 阴囊 scrotum
- 10 卵巢 ovary
- 12 阴道 vagina
- 14 肾静脉 renal vein
- 16 子宫 uterus



图IX-29 生殖器官（♀） The genital organs（♀）

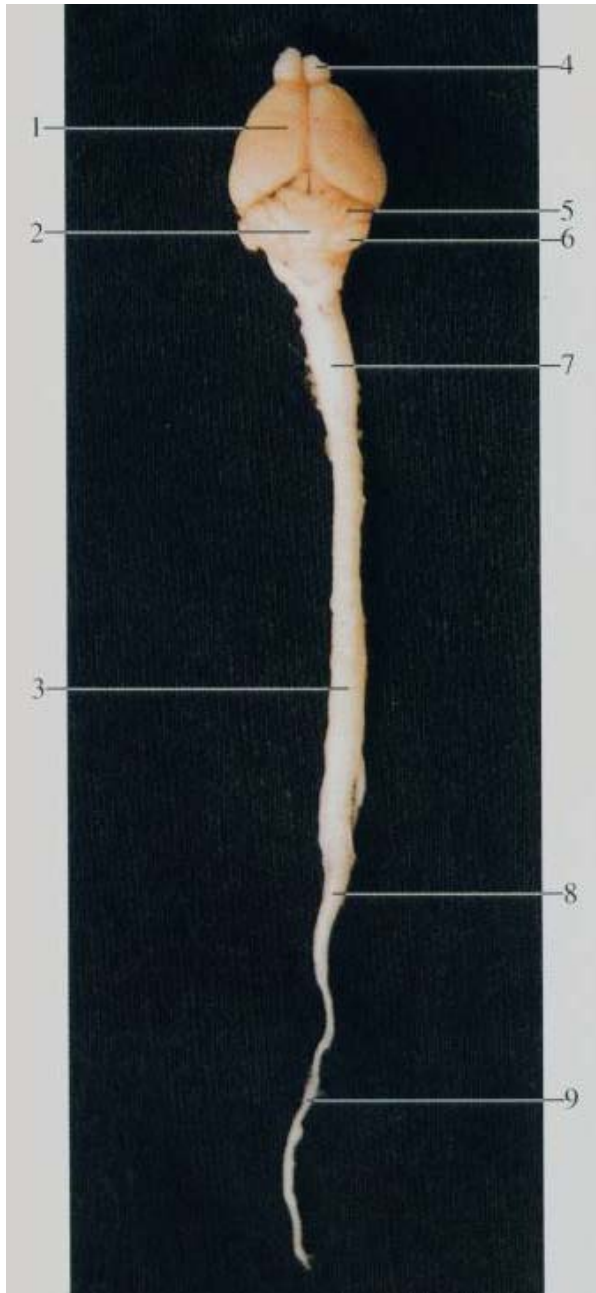


图IX-30 脑与脊髓背面(1) The brain and spinal cord. Dorsal aspect (1)

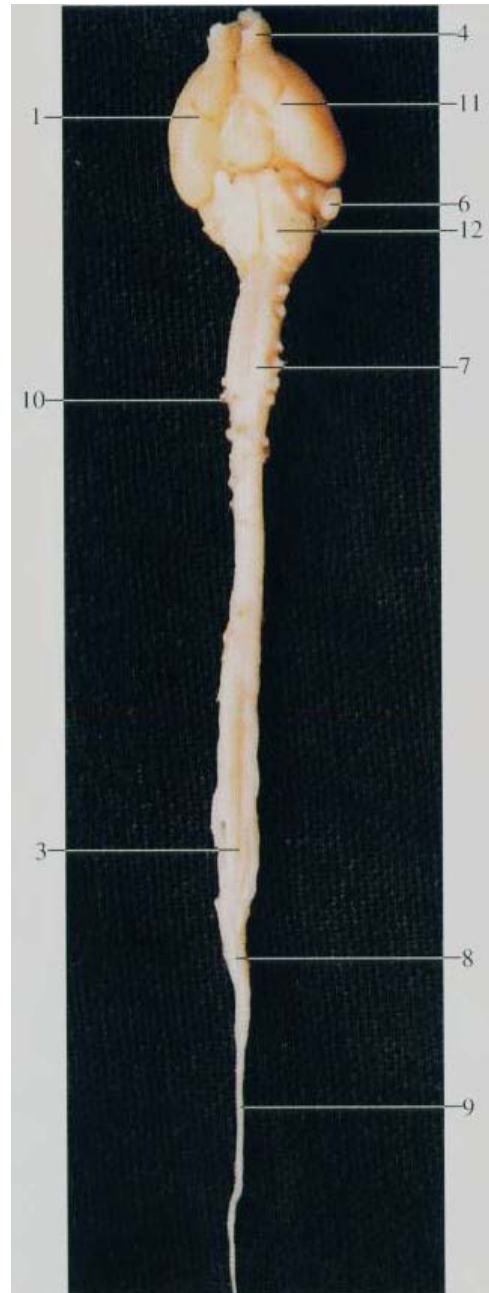


- |  |                                 |
|--|---------------------------------|
| 1 肾静脉 renal vein                           | 2 后腔静脉 postcaval vein           |
| 3 卵巢 ovary                                 | 4 输卵管 uterine tube              |
| 5 髂总静脉 common iliac vein                   | 6 脂肪 fat                        |
| 7 肾 kidney                                 | 8 子宫 uterus                     |
| 9 阴道 vagina                                | 10 阴门 vulva                     |
| 11 大脑 cerebrum                             | 12 小脑绒球 flocculus of cerebellum |
| 13 颈膨大 cervical enlargement                | 14 背斜方肌 trapezius dorsi muscle  |
| 15 腰骶膨大 lumbosacral enlargement            | 16 终丝 filum terminate           |
| 17 嗅球 olfactory bulb                       | 18 小脑 cerebellum                |
| 19 小脑蚓 vermis                              | 20 背阔肌 latissimus dorsi muscle  |
| 21 腹外斜肌 external oblique muscle of abdomen | 22 脊髓圆锥 conus medullaris        |

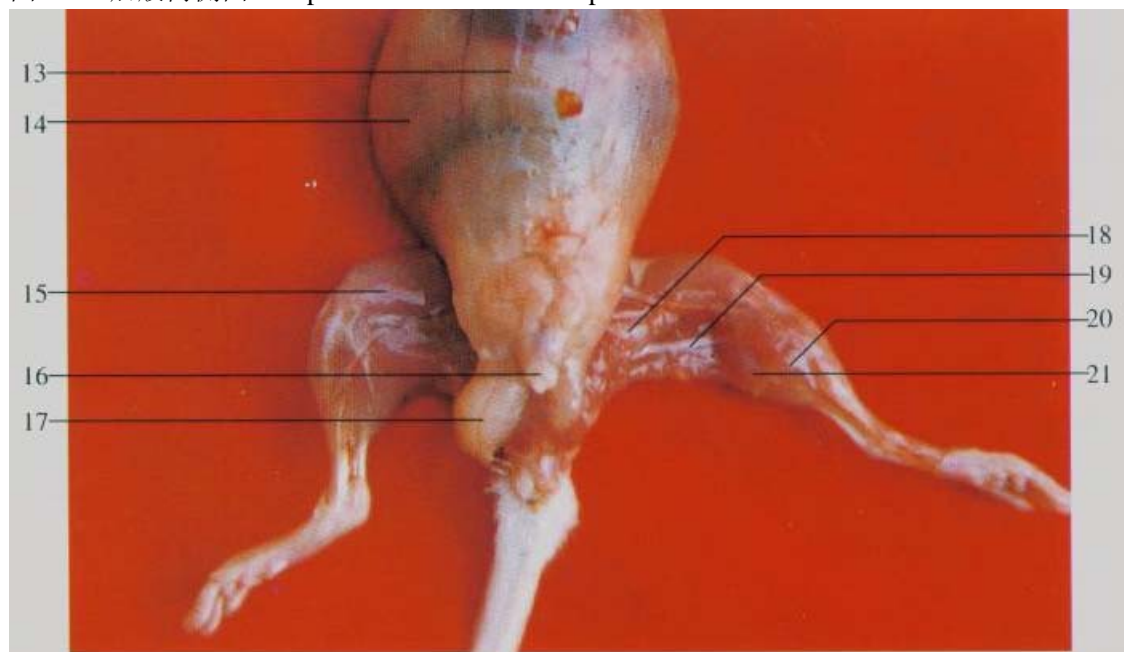图IX-31 脑与脊髓背面(2)The brain and spinal cordDorsal aspect (2)



图IX-32 脑与脊髓腹面 The brain and spinal cord. Ventral aspect



图IX-33 后肢内侧面 The posterior limb. Medial aspect



- 1 大脑炎 cerebrum
- 2 小脑蚓 vermis
- 3 腰骶膨大 lumbosacral enlargement
- 4 嗅球 olfactory bulb
- 5 小脑 cerebellum
- 6 小脑绒球 flocculus of cerebellum
- 7 颈膨大 cervical enlargement
- 8 脊髓圆锥 conus medullaris
- 9 终丝 filum terminate
- 10 脊神经 spinal nerve
- II 视神经 optic nerve
- 12 延髓 medulla oblongata
- 13 腹直肌 rectus abdominis muscle
- 14 腹外斜肌 external oblique muscle of abdomen
- 15 股直肌 rectus femoris muscle
- 16 阴茎 penis
- 17 阴囊 scrotum
- 18 内收肌 adductor medial muscle
- 19 坐骨神经 sciatic nerve
- 20 趾深屈肌 flexor digitorum profundus muscle
- 21 腓肠肌 gastrocnemius muscle